C-SHAPED CANALS FROM DIAGNOSIS TO TREATMENT - A REVIEW

[1]Lakshya Rani.S, [2]S. Delphine Priscilla Anthony

Type of manuscript: Review

Running title: C-shaped canals from diagnosis to treatment

Lakshya Rani.S
Graduate student,
Saveetha Dental College, SIMATS, Chennai, India.

S. Delphine Priscilla Anthony
Senior lecturer,
Department of Conservative Dentistry and Endodontics, Saveetha Dental College, SIMATS,
Chennai, India.

Corresponding Author:
S. Delphine Priscilla Anthony
Senior lecturer,
Department of Conservative Dentistry and Endodontics, 162, Poonamallee high road,
Saveetha Dental College and Hospitals, SIMATS
Chennai – 600077

***Abstract*: This review explains about the diagnosis and management: A thorough knowledge of the root canal morphology is required for successful endodontic treatment. One of the most important anatomic variations is the "C" shape configuration of the canal system. C shape canal is a single ribbon shaped orifice system With a 180 degree arc, starts at the mesiolingual line angle and sweeps around the buccal to the end at the distal aspect of the pulp chamber and is mostly seen in mandibular second molars. Careful assessment of preoperative radiograph is a key step for its subsequent treatment management and this assessment might impact greatly on the treatment outcomes. Because of the great challenges in the diagnosis and treatment of C - shape configuration and critical need for its proper management this review will address about the C shaped canals from diagnosis to treatment.**

INTRODUCTION

A complete and thorough knowledge of the tooth morphology and variations in the root canal anatomy is necessary for effective and successful root canal therapy along with diagnosis, treatment planning and clinical [1,4].C-shaped canal configuration is regarded as one such and most important variations in the root canal system [1,4,8].The term C-shaped canal configuration which was documented for the first time in the endodontic literature by Cooke and Cox in 1979, is so named for the cross sectional morphology of the root and root canal[1,2,3,4,5,8]. C-shaped canals are mostly found in mandibular second molars. Their main anatomical feature is the presence of a fin connecting root canals.
Instead of having discrete orifices, the pulp chamber of the C-shaped canal is a single-shaped orifice with a 180° arc (or more), which, in mandibular molars, starts at the mesiolingual line angle and sweeps around the buccal to the end at the distal aspect of the pulp chamber. The root structure can have a wide range of anatomic variations before the orifice level [5,6,7,8].These variations can be classified into two basic groups: (1) those with a single, ribbon-like, C-shaped canal from orifice to apex and (2) those with three or more distinct canals below the C-shaped orifice. Fortunately, C-shaped canals with a single swath of canal are the exception rather than the rule [8,9] . To facilitate effective management , recognition of C-shaped canal configuration is very important so that it prevents damage that might put the the tooth in harmful complications [4] .Because of the great challenges in the diagnosis and treatment of C-configuration and critical need for its proper management , this article aims at discussing about the etiology, classification, epidemiology,diagnosis , treatment and management of the C-shaped canal configuration.

ETIOLOGY

C-shaped canals appear when fusion of either the lingual or buccal aspect of the mesial and distal roots. This fusion remains irregular and the two roots stay connected by an interradicular ribbon. The floor of the pulp chamber is deep and has an unusual anatomic appearance. Two or three canals may be found in the C-shaped groove, or the C-shape may be continuous throughout the root length.Hertwig's epithelial sheath, which determines the shape and the number of roots , bends in a horizontal plane below the cementoenamel junction and fuses in the center leaving openings for roots[8,9].The main cause of formation of the C-shaped roots is the failure of the Hertwig's epithelial root sheath to fuse on the lingual or buccal root surface. The C-shaped roots always contain a C- shaped canal. The formation of the C-shaped root by coa- lescence may also occur because of the deposition of the cementum with time [8,11].

CLASSIFICATION

MELTONS CLASSIFICATION:

Melton et al.,[13]in 1991 proposed the following classification of C-shaped canals based on their cross-sectional shape(Fig 1)

Figure 1: Classification of c- shaped root canal configuration according to Melton

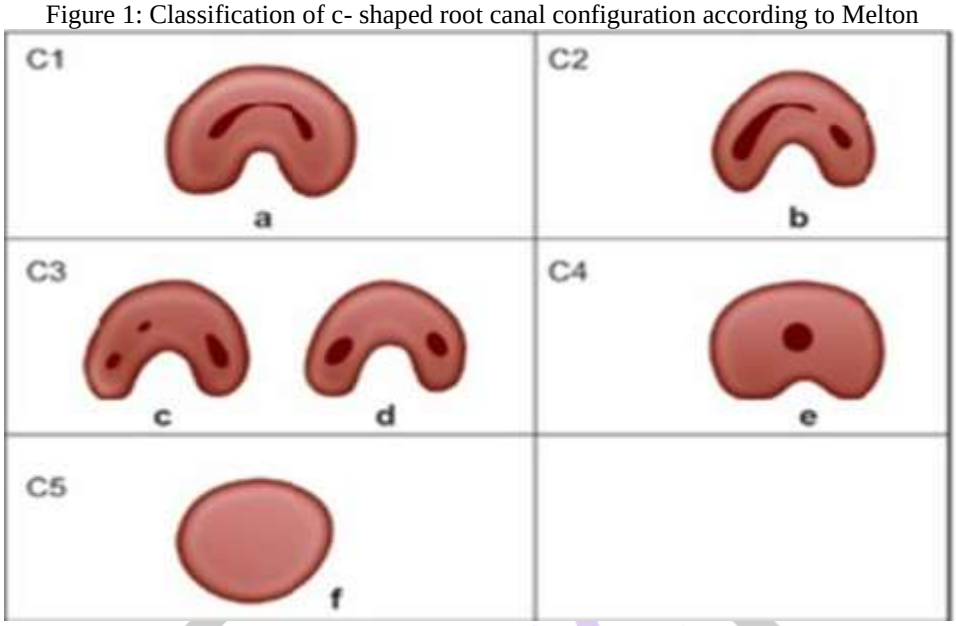

Category I: Continuous C-shaped canal running from the pulp chamber to the apex defines a C-shaped outline without any separation.
Category II: The semicolon-shaped orifice in which dentine separates a main C-shaped canal from one mesial distinct canal.
Category III: Refers to those with two or more discrete and separate canals

Subdivision I: C-shaped orifice in the coronal third that divides into two or more discrete and separate canals that join apically.
Subdivision II: C-shaped orifice in the coronal third that divides into two or more discrete and separate canals in the mid root to the apex.
Subdivision III: C-shaped orifice that divides into two or more discrete and separate canals in the coronal third to the apex.
Fan et al,.[8] in 2004 modified Melton's method of classification into the following categories (Fig 2)

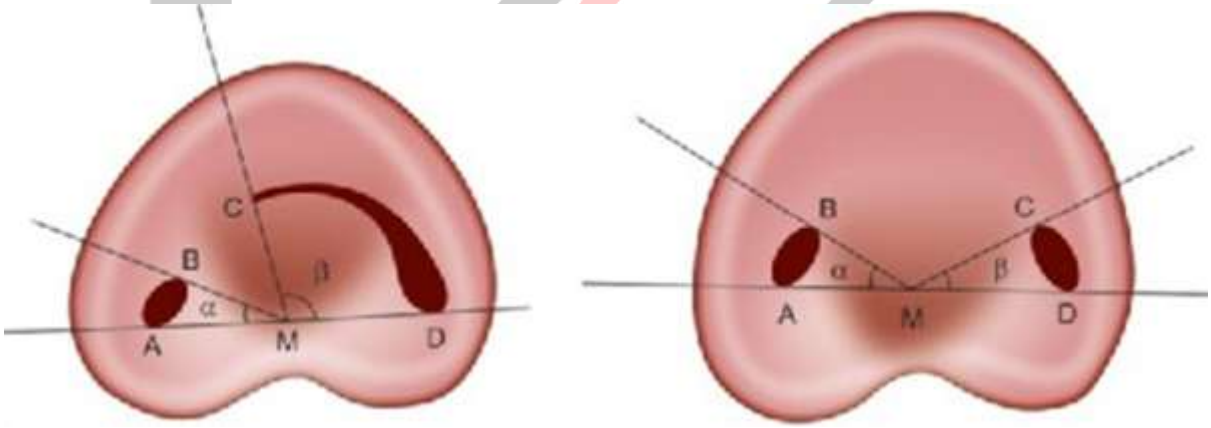

Figure 2: Meltons modified method of classification of C – shaped root canal configuration.

- Category I (C1): The shape was an interrupted ‘C’ with no separation or division.
- Category II (C2): The canal shape resembled a semicolon resulting from a discontinuation of the ‘C’ outline, but either angle or should be no less than 60°.
- Category III (C3): Two or three separate canals and both angles, and were less than 60°.
- Category IV (C4): Only one round or oval canal in that crosssection.
- Category V (C5): No canal lumen could be observed (which is usually seen near the apex only).

Fan's classification (Radiographic classification)

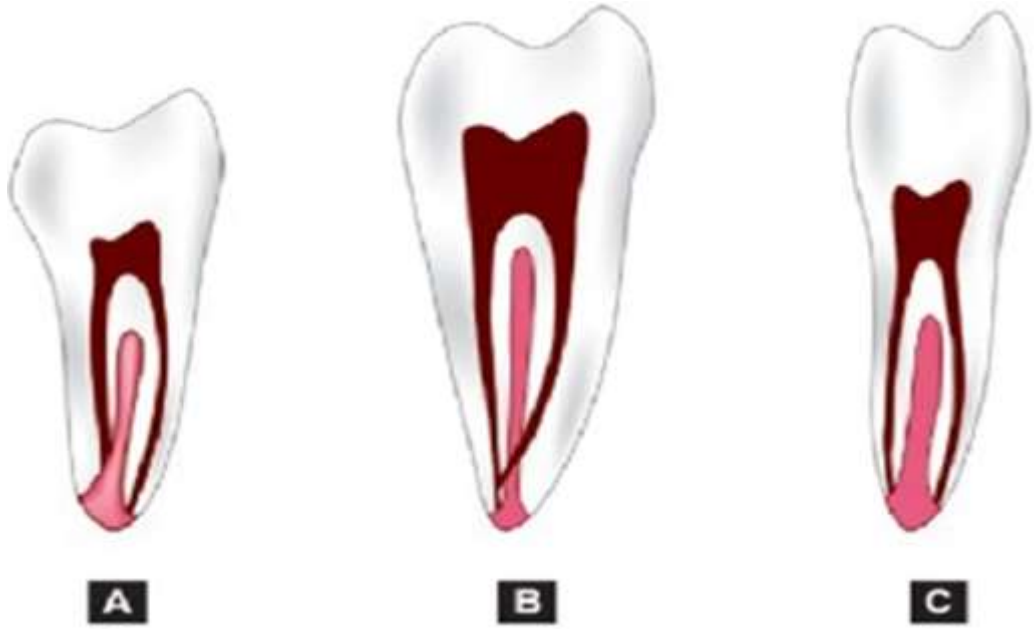

Fan et al classified C-shaped roots according to their radio-graphic appearance into

TYPEl: Conical or square root with a vague, radiolucent longitudinal line separating the root into distal and mesial parts. There was a mesial and a distal canal that merged into one before exiting at the apical foramen (foramina).
TYPE ll: Conical or square root with a vague, radiolucent longitudinal line separating the root into distal and mesial parts. There was a mesial and a distal canal, and the two canals appeared to continue on their own pathway to the apex.
TYPE lll: Conical or square root with a vague, radio-lucent longitudinal line separating the root into distal and mesial parts. There was a mesial and a distal canal, one canal curved to and superimposed on this radiolucent line when running toward the apex, and the other canal appeared to continue on its own pathway to the apex.

ANATOMIC FEATURES

The following are the features in relation to the external root anatomy and configuration of the pulp chamber and the root canal system usually found in C-shaped mandibular molars, though similar features may be found in C-shaped maxillary molars and mandibular premolars.

Roots

A conical or square configuration is characteristic of roots having a C-shaped canal.[11,22] the root configuration of molars having this canal shape is also described by fusion of either the facial or lingual aspect of the mesial and distal roots. The roots show an occluso-apical groove on the buccal or lingual surface, that represent the line of fusion between mesial and distal roots. The surface opposite this radicular groove is convex.[13] Peiris et al.,[20] referred to the C-shaped roots of mandibular second molars as being 'gutter-shaped'.

Pulp chamber

The pulp chambers of teeth with C-shaped canals principally have larger apico-occlusal dimension with a low bifurcation.[19] This ends up in a deep pulp chamber floor, that has uncommon anatomical configuration.[21] The connecting slit that offers the tooth its name of "C-shaped" could have closure to the buccal or lingual. If the buccal portion of the mesial and distal roots is fused, the slit goes through the area of fusion, so the "C" is closed to the lingual. If the lingual portion of the roots is fused, then the "C" is closed to the buccal.[18]

Root canal system

The root canal system of C-shaped canals shows broad, fan-shaped communications from the coronal to the apical third of the canal. The canal(s) change from the coronal aspect of the root. For example: a continuous C-shaped canal would change to a semicolon configuration within the mid root and then becomes continuous C-shape in the apical third of the root or vice versa.[13] accessory and lateral canals, inter-canal communications and apical delta will be found in a very prevalence of 11-41%, within the apical region of C-shaped canals.[23] Cross-sectional C-shaped canal morphology reveals thinner lingual walls than buccal with the bottom value measured being 0.26 mm.[17] the various intricacies within the C-shaped canal anatomy are outlined in the section on classification.

EPIDEMIOLOGY

The C-shaped canal configuration shows an ethnic predilection. Many studies says that it has been frequently been reported in countries belonging to the Asian continent. East Asian population groups like Chinese (0.6%-41.27%) and Koreans (31.3%-45.5%) display a high prevalence of this variant.[9,14,15,21-23,27,28] Among the South Asian countries, Burmese population showed a prevalence of 22.4%, which was much higher than the Indian, Thai or Sri Lankan population.[11,13,17,18,20,24,26] Higher incidence of C-shaped anatomy was documented in Lebanese population (19.1%) as compared to the other West Asian population groups (Iranian, Jordanian, Saudi Arabian).[5,10,12,19] An incidence of 10% was reported in Sudanese population from the African continent.[16]Canal configuration has been shown to have a high prevalence in mandibular second molars with a percentage ranging between 2.7%-45.5%.[1,5,7,9-23,30-32] Incidence studies in mandibular premolars have been reported in Chinese, Indian and Iranian population, with the highest frequency being reported in the Chinese population (29.7%).[24-27,33] The C-shaped variation in canal anatomy has also been reported in maxillary first molars (0.12%), maxillary third molars (4.7%), mandibular third molars (3.5%-4%) and mandibular second premolars (1%). [3,28,29,34] .There is no correlation of C-shaped canal configuration with gender and also with age and tooth position. Bilateral occurrence of C-shaped canals has been reported in a percentage of 70%-81%.[22].

DIAGNOSIS AND MANAGEMENT

Preoperative radiographic diagnosis

The preoperative awareness of a C-shaped canal configuration before treatment can facilitate effective management. A preoperative radiograph and an additional radiograph from 20° mesial or distal projection may be the only noninvasive means clinically to provide clues about the canal morphology [24,25] Cooke and Cox [26] stated that it was impossible to diagnose C-shaped canals on the preoperative radio- graph, but in the study of Haddad et al.,
[6] almost all preoperative radiographs showed common characteristics. These characteristics formed a typical image that allowed prediction of the existence of this anatomic condition. In fact, most radiographs revealed radicular fusion or proximity, a large distal canal, a narrow mesial canal, and a blurred image of a third canal in between. The canal orifice may present with a “C” shape but not always, and, when it does, it is no guarantee that it continues apically as a single canal [28] .
Radiographs taken while negotiating the canals may reveal two characteristics for such canal configuration: instruments tending to converge at the apex and/or may exit at the furcation
[29] The latter sometimes may resemble a perforation of the furcation [29, 30,13,32]. This radiographic appearance is more likely to occur in category I. The presence of instruments or filling materials in the furcation area in combination with the poorly distinguished floor of the pulp chamber can lead to radiographic recognition of “C” configuration ration.Differential diagnosis of C-shaped molars from furcation perforation, on the basis of radiographs, can be aided in cases of interpretation of more than one radiograph [12]. Also, using a third-generation apex locator with the ability of reading canal lengths in the presence of electrolytes, should help to distinguish between the two [13].
The root configuration of molars having this canal shape may be represented as a single fused root or as two distinct roots with a communication, the latter of which may not be very obvious at first glance [28]. Thus, its recognition is improbable until access to the pulp chamber has been achieved. Radiographic recognition may be of particular importance for prosthodontists, especially in cases in which a cast post involving the root canal is planned [12]. Preoperative radiographs show close fused roots or images of two distinct roots. This occurs when the fin is thin and thus, not visible on the radiograph, and makes clinical recognition of the C-shaped canal un- likely until access to the pulp chamber has been achieved [30,6] .Radiographic interpretation is overall more effective when based on film combinations (“preoperative and working length radiographs” or “preoperative and final radiographs” or “all three radiographs”) than on single radiographs. Among the latter, working length radio- graphs are more helpful than the preoperative and final ones, whereas preoperative radiographs are the least effective in diagnosing the C- shaped cases [12].

It should be noted that using a radiograph showing files set to the canal terminus to diagnose and to determine canal morphology may not give the results expected. In some instances, it may be difficult to distinguish between C-shaped canal or one with single or three canals joining apically. Thus, it is necessary to confirm the diagnosis by exploring the access cavity [18.35].

Preoperative clinical diagnosis:

Clinical recognition of C-shaped canals is based on definite ob- servable criteria (i.e., the anatomy of the floor of the pulp chamber and the persistence of hemorrhage or pain when separate canal orifices were found) [25]
The pulp chamber in teeth with C-shaped canals may be large in the occlusoapical dimension with a low bifurcation. Alternatively, the canal can be calcified, disguising its C-shape. At the outset, several orifices may be probed that link up on further instrumentation[7]. In a true C- shaped canal, it is possible to pass an instrument from mesial to distal aspect without obstruction. In other configurations, such passage is impeded by discontinuous dentine bridges [14]. If a file could not be passed through the isthmus of the pulpal floor during clinical inspec- tion, the practitioner might consider the root canal as being separated. But in the laboratory analysis, these canals might merge just below the isthmus area [35].
Fused roots and C-shaped roots may present with narrow root grooves that predispose to localized periodontal disease, which may in fact be the first diagnostic indication of such anatomic variance. It is equally probable that the groove will occur on the buccal or lingual surface [14,18]. When a deep groove is present on lingual or buccal surfaces of the root, a C- shaped canal is to be

expected [10].
Clinically, when a C-shaped canal orifice is observed under the operating microscope, one cannot assume that such a shape continues throughout its length. New methods should be developed to diagnose not only the existence, but the configuration of the entire C-shaped canal system [10]. It is possible to overlook the fact that the canal may be connected in the coronal portion yet separated in the apical region. When the canal orifice looks continuously connected at the subpulpal level, a separate root canal exiting at the apical level should be suspected[35].

The pulp chamber in teeth with C-shaped canals may be large in the occlusoapical dimension with a low bifurcation. Alternatively, the canal can be calcified, disguising its C-shape. At the outset, several orifices may be probed that link up on further instrumentation In a true C- shaped canal, it is possible to pass an instrument from mesial to distal aspect without obstruction[2].

MANAGEMENT

Canal System Identification and Preparation

The access cavity for teeth with a C-shaped root canal system varies considerably and depends on the pulp morphology of the specific tooth. Initial canal-system recognition occurs after achievement of routine endodontic access and removal of tissue from the pulp chamber[31].
If a C-shaped root is present, two of Melton's three categories (category I and II) should be evident (in category III, two or three separate canals may appear initially as a typical three- canal orifice mandibular molar). In all categories, the mesiobuccal and distal canal spaces usually can be prepared normally. Also, Gates-Glidden burs should not be used to prepare the mesiobuccal and buccal isthmus areas[32].
Because of the large volumetric capacity of the C-shaped canal system, housing transverse anastomoses and irregularities and continuous circumferential fling along the periphery of the C canal is irrigated with copious amounts of 5.25% NaOCl are often necessary to ensure maximum tissue removal and cessation of bleeding[33,34]. HAFI (Hedstrom files) are especially effective for Efficient tissue removal. If hemorrhaging persists, then ultrasonic removal of tissue or placement of calcium hydroxide may be used between appointments to enhance tissue removal and control hemorrhage[33].
Alternative canal cleaning techniques, such as those that use ultrasonics, would be more effective. An increased volume of irrigant and deeper penetration with small instruments using sonics or ultrasonics may allow for more cleansibility in fan-shaped areas of the C- shaped canal[35] Although ultrasonic preparation may effectively remove tissues from narrow C-shaped canal ramifications, aggressive instrumentation may cause perforation[35,34].

CANAL SYSTEM OBTURATION

Technique modifications can be done for obturation of C-shaped canals. The preparation and obturation of mesiolingual and distal canal spaces can be done as standard canals.If lateral condensation is the only method used for obturation, the sealing of buccal isthmus would be difficult. As a result , the isthmus might not be prepared with a adequate fare to allow deep placement of the spreader , application of thermoplasticized gutta-percha is more applicable[13,17,18]

ENDODONTIC SURGERY

The clinician must be aware of the impact this anatomy has when surgical endodontics is indicated. The absence of furca contraindicates hemisection or root amputation. The intercanal communications or fins visualized on the serial sections reinforce the difficulty the clinician would encounter after apicoectomy with the retropreparation and eventual retrofilling. If endodontic surgical intervention is indicated for a molar with C-shaped root canal anatomy, strong considerations should be given to extraction, retrofilling, and intentional replantation[19].

RESTORATION AND PROGNOSIS

Technique modification may be required for restoration of C-shaped roots. If post placement for a crown core is desired, use of only the distal canal should be considered. Proper post- canal adaptation and stress distribution is more likely to result in the tubular distal canal. Placement of posts or antirotational pins in the mesiolingual and mesiobuccal areas of C- shaped root invites perforation. Also, post width should be minimized[11].It should be remembered that there is a higher risk of root perforation at the thinner lingual walls of C- shaped canals during shaping and post space preparation procedures. Both buccal and lingual canal walls are frequently narrower at mesial locations[13].
During follow-up radiographic examination, the dentist should look for furcal breakdown because that region is the most difficult to obturate and is associated with the greatest risk of perforation. Restorations with failure in the furca have a poor prognosis. If the failure results from an apical etiology and apical surgery is not possible, viable options include extraction, extraoral retrofilling and replantation. Because C-shaped roots generally are conical, they are easy to extract without fracture[14,15,16].
When sound principles of cleaning and shaping, obturation and restoration are followed, the long-term prognosis for the C-shaped root retention equals that of other molars, but cautious optimism would seem most appropriate when prognosticating the success of the root canal treatment of a C-shaped canal[20,21,22]
Because C-shaped roots generally are conical, they are easy to extract without fracture. When sound principles of cleaning and

shaping, obturation and restoration are followed, the long- term prognosis for the C-shaped root retention equals that of other molars, but cautious optimism would seem most appropriate when prognosticating the success of the root canal treatment of a C-shaped canal[25].

CONCLUSION

The early recognition of these configurations facilitates cleaning, shaping and obturation of the root-canal system. It should be noted that using a radiograph showing files set to the canal terminus to diagnose and to determine canal morphology may not give the results expected. In some instances, it may be difficult to distinguish between C-shaped canal or one with single or three canals joining apically. Thus, it is necessary to confirm the diagnosis by exploring the access cavity. Knowledge and recognition of canal configuration facilitates more effective canal identification and unnecessary removal of healthy tooth structure in an attempt to search for missing canals. All the cases were treated in multiple sittings to rule out the possibility of a missed canal. Further long-term clinical studies are needed to substantiate the diagnosis of this variant in mandibular second molars using various diagnostic methods for a better understanding of this variant to facilitate cleaning, shaping and obturation of the root canal system.

REFERENCES

[1] Rahimi S (Department of Endodontics, Tabriz Dental School, Tabriz University of Medical Sciences, Tabriz, Iran. rahimidarehchi@yahoo.com) Shahi S, Lotfi M, Zand V, Abdolrahimi M, Es'haghi R. Root canal configuration and the prevalence of C-shaped canals in mandibular second molars in an Iranian population. J Oral Sci. 2008 Mar;50(1):9–13.
[2] Barril I, Cochet JY, Ricci C. Treatment of a canal with a 'C' configuration. Rev Fr Endod. 1989 Sep;8(3):47–58.
[3] Barnett F. Mandibular molar with C-shaped canal. Endod Dent Traumatol. 1986 Apr;2(2): 79–81.
[4] Orban B, Mueller E. The development of bifurcation of multi-rooted teeth. J Am Dent Assoc. 1929;16:297–319.
[5] Jafarzadeh H, Wu YN. The C-shaped Root Canal Configuration: A Review; J Endod 2007; 33: 517–523.
[6] Haddad GY, Nehme WB, Ounsi HF. Diagnosis, classification, and frequency of C Shaped canals in mandibular second molars in the Lebanese population; J Endod 1999; 25: 268 –71.
[7] De Moor RJ (Department of Operative Dentistry and Endodontology, Dental School, Ghent University Hospital, Belgium). C-shaped root canal configuration in maxillary first molars. Int Endod J. 2002 Feb;35(2):200–208.
[8] Fan B (Key Lab for Oral Biomedical Engineering of Ministry of Education, Endodontic Center, School & Hospital of Stomatology, Wuhan University, Wuhan, China.) Cheung GS, Fan M, Gutmann JL, Bian Z. C-shaped canal system in mandibular second molars: Part I– Anatomical features. J Endod. 2004 Dec;30(12):899–903
[9] Cohen S, Burns RC. Pathways of the pulp. 8th ed. St. Louis: Mosby, 2002;196 –229.
[10] Cleghorn BM, Christie WH, Dong CC. Root and root canal morphology of the human permanent maxillary first molar: A literature review. J Endod 2006;32:813-21
[11] Manning SA. Root canal anatomy of mandibular second molars. Part II. C-shaped canals. Int Endod J 1990;23:40 –5.
[12] Lambrianidis T, Lyroudia K, Pandelidou O, Nicolaou A. Evaluation of periapical radiographs in the recognition of C-shaped mandibular second molars. Int Endod J 2001;34:458 – 62.
[13] Melton DC, Krell KV, Fuller MW. Anatomical and histological features of C-shaped canals in mandibular second molars. J Endod 1991;17:384 – 8.
[14] Min Y, Fan B, Cheung GS, Gutmann JL, Fan M. C-shaped canal system in mandibular second molars Part III: The morphology of the pulp chamber floor. J Endod 2006;32:1155-9.
[15] Ordinola-Zapata R, Bramante CM, de Moraes IG, Bernardineli N, Garcia RB, Gutmann JL. Analysis of the gutta-percha filled area in C-shaped mandibular molars obturated with a modified MicroSeal technique. Int Endod J 2009;42:186-97.
[16] Carlsen O, Alexandersen V, Heitmann T, Jakobsen P. Root canals in one-rooted maxillary second molars. Scand J Dent Res 1992;100:249-56
[17] Chai WL, Thong YL. Cross-sectional morphology and minimum canal wall widths in C- shaped roots of mandibular molars. J Endod. 2004;30:509–12.
[18] Weine FS. The C-shaped mandibular second molar: Incidence and other considerations. Members of the Arizona Endodontic Association. J Endod. 1998;24:372–5.
[19] Gulabivala K, Opasanon A, Ng YL, Alavi A. Root and canal morphology of Thai mandibular molars. Int Endod J. 2002;35:56–62.
[20] Velmurugan N, Sandhya R. Root canal morphology of mandibular first premolars in an Indian population: A laboratory study. Int Endod J. 2009;42:54–8.
[21] Seo MS, Park DS. C-shaped root canals of mandibular second molars in a Korean population: Clinical observation and in vitro analysis. Int Endod J 2004;37:139-44
[22] Jerome CE. C-shaped root canal system: Diagnosis, treatment and restoration. Gen Dent. 1994;42:424–7.
[23] Cheung GS, Yang J, Fan B. Morphometric study of the apical anatomy of C-shaped root canal systems in mandibular second molars. Int Endod J. 2007;40:239–46.
[24] Fan B, Cheung GS, Fan M, Gutmann JL, Fan W. C-shaped canal system in mandibular second molars: Part II–Radiographic features. J Endod 2004;30:904 – 8.
[25] De Moor RJ. C-shaped root canal configuration in maxillary first molars. Int Endod J 2002;35:200 – 8
[26] Cooke HG 3rd, Cox FL. C-shaped canal configurations in mandibular molars. J Am Dent Assoc 1979;99:836 –9.
[27] Yin X, Cheung GS, Zhang C, Masuda YM, Kimura Y, Matsumoto K. Micro-computed tomographic comparison of nickel-

titanium rotary versus traditional instruments in C-shaped root canal system. J Endod 2010;36:708-12.
[28] Solomonov M, Paqué F, Fan B, Eilat Y, Berman LH. The challenge of C-shaped canal systems: A comparative study of the self-adjusting file and ProTaper. J Endod 2012;38:209-14.
[29] Neelakantan P, Subbarao C, Subbarao CV, Ravindranath M. Root and canal morphology of mandibular second molars in an Indian population. J Endod 2010;36:1319-22.
[30] Zhang R, Wang H, Tian YY, Yu X, Hu T, Dummer PM. Use of cone-beam computed tomography to evaluate root and canal morphology of mandibular molars in Chinese individuals. Int Endod J 2011;44:990-9.
[31] Khedmat S, Assadian H, Saravani AA. Root canal morphology of the mandibular first premolar in an Iranian population using cross-sections and radiography. J Endod 2010;36:214-7.
[32] Xu X, Wang DG, Wang XY. Clinical significance of the abnormal radiographic mani- festations of pulp cavity. Shanghai Kou Qiang Yi Xue 1996;5:85– 6.
[33] Gutmann JL, Rakusin H. Perspectives on root canal obturation with thermoplasticized injectable gutta-percha. Int Endod J. 1987 Nov;20(6):261–270.
[34] Kuzekanani M, Haghani J, Nosrati H. Root and canal morphology of mandibular third molars in an Iranian population. J Dent Res Dent Clin Dent Prospects 2012;6:85-8.
[35] Al-FouzanKS.C-shapedrootcanalsinmandibularsecondmolarsinaSaudiArabian population. Int Endod J 2002;35:499 –504.