

# CBCT report of three cases of cysts and its radiographic presentations.

<sup>1</sup>Dr.Rashmi Sapkal,<sup>2</sup>Dr.Aqsa Tamboli,<sup>3</sup>Dr.Husna Patel,<sup>4</sup>Dr.Shraddha Supnekar,<sup>5</sup>Dr.Nikhil Diwan

<sup>1</sup>Professor, <sup>2</sup>Postgraduate, <sup>3</sup>Postgraduate, <sup>4</sup>Sr.Lecturer, <sup>5</sup>Professor

<sup>1,2,3,4,5</sup>Dept.of Oral medicine& radiology,M.A.Rangoonwala college of dental sciences & research centre,Pune.

**Abstract :** Accurate diagnosis with imaging and treatment planning are key to performing any surgical procedure. Panoramic radiography is commonly used in dentistry to aid in clinical diagnosis, treatment, but has limitations such as overlapping anatomical areas of interest for diagnosis. The invention of computed tomography (CT) revolutionized digital imaging, although there were limitations, such as 2-dimensional imaging properties such as distortion, magnification, and superposition. Cone Computed Tomography (CBCT) is rapidly gaining interest in the medical fraternity. was designed to compensate for some of the limitations of panoramic and CT imaging. CBCT has been routinely used in dentistry since its inception for its numerous advantages such as 3-dimensional and multiplanar imaging. Linear, curved and angular measurements can be made along with area and volume and density calculations. All this with less radiation exposure compared to conventional computed tomography (CT). In this case, three cases of jaw cysts with different radiographic features were presented, and the role of CBCT in these cases flooded us with vast radiographic information that paved the way for precise surgical management.

**KEYWORDS-CYST,CBCT,3D IMAGING,MAXILLOFACIAL RADIOLOGY**

## 1.INTRODUCTION-

CBCT is used in medicine and in all dental fields including orthodontics, periodontics and endodontics. 1.2 In oral and maxillofacial surgery, CBCT plays a key role in monitoring the mandibular canal, impaction, dentoalveolar surgery, implants, removal of tumors and cysts. When treating cysts and tumors, it is essential to measure the lesion from different angles to study its spread. 3.4 S CBCT exists error less than 1% compared to other conventional methods. 5.6

It also helps prevent complications during surgery, reduces functional deterioration after surgery. 7,8 Here we present a number of cases consulted with CBCT imaging and its importance in the diagnosis of cysts and tumors, emphasizing the direct ordering of CBCT when a cyst or tumor is suspected.

## 2. CASE PRESENTATION-

### 2.1. Case 1-

A 28-year-old female reported with a chief complaint of swelling in her lower left front tooth region associated with pain on mastication. History revealed an insidious onset of swelling which was not noticed by the patient until the pain had started. There was no other contributory history. Clinical examination revealed a swelling in the region of 31, 32,33,41,42 &43 with significant buccal and lingual cortical expansion. There was no other discharge or bleeding. She was ordered a CBCT (carestream 9300) directly in order to study the extent of the lesion. The scan revealed a large unilocular, expansile and osteolytic lesion of about Antero-posteriorly: - 10.7mm,Supero -inferiorly: - 18.2mm & Mesio-distally: - 18.4mm in diameter in the front mandible extending from 43 to 33region with well-defined thin sclerotic border which was not continuous. Internal structure was uniformly radiolucent with no calcifications (Figure 1 (a)). There was evidence of loss of labial & lingual cortical plate. The above radiographic findings suggested that the lesion is a radicular cyst involving apices of 31,32,33,41,42,&43.

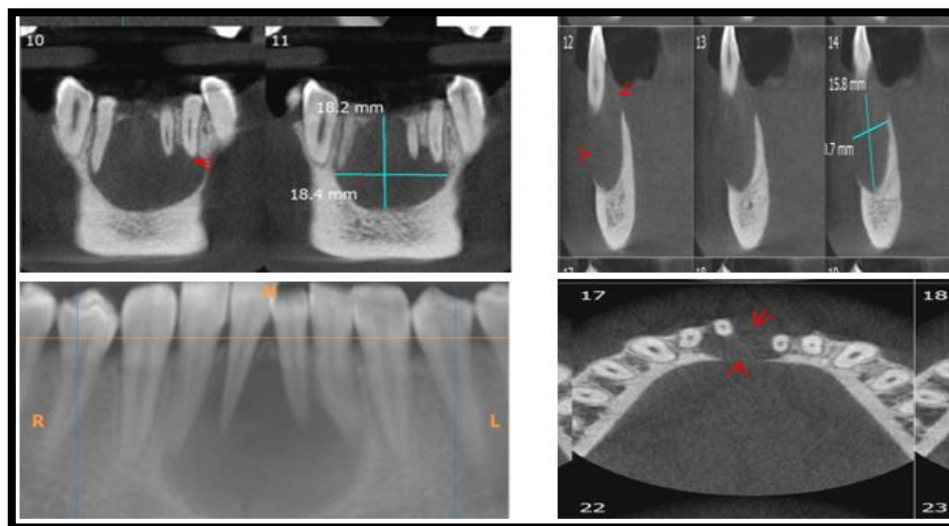


Fig.1-RADICULAR CYST



## 2.2. Case 2

A 16-year-old female reported with a chief complaint of swelling in his lower right back tooth region associated with pain on mastication. History revealed an insidious onset of swelling which was not noticed by the patient until the pain had started. There was history on extraction of 46, due to caries. Clinical examination revealed a swelling in the region of 45, 46, 47 with significant buccal and lingual cortical expansion. There was no other discharge or bleeding. She was ordered a CBCT (carestream 9300) directly in order to study the extent of the lesion. The scan revealed a large Well defined, multilocular radiolucency with corticated border noted in the region of 44, 45, 46 (edentulous) of about dimensions as Antero-posteriorly: - 18.5mm, Supero -inferiorly: - 16.9mm & Mesio-distally: - 11.1mm, in the right posterior mandible extending anteriorly from 45 and posteriorly to 47 region with well-defined thin sclerotic border which was not continuous. Evidence of breach and thinning in the continuity of buccal cortical plate. The lesion was more pronounced on the buccal side with expansion of buccal cortical plate. There is erosion of superior alveolar crest and erosion of superior aspect of inferior alveolar nerve canal. Root resorption noted with 45. The sagittal and coronal and axial sections showed significant expansion of buccal and lingual cortices (Figures 3 and 4). The above radiographic findings suggested that the lesion is a benign cyst/tumour with a differential diagnosis of Unicystic ameloblastoma and Odontogenic Keratocyst.

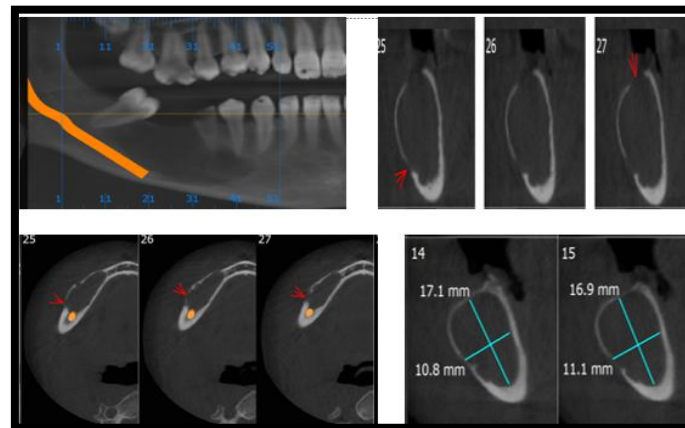


Fig.2-BENIGN CYST

## 2.3. Case 3

A 40-year-old female reported with a chief complaint of pain & swelling in lower left front teeth region. Clinical examination revealed severe attrition with 32 along with grade I mobility with 33 which was root canal treated before 6 months. IOPA revealed lesion involving 32, 33. For detail evaluation CBCT was advised. CBCT revealed a Single, well defined radiolucency noted with 32 & 33 extending Mesio-distally from distal aspect of 32 till the mesial aspect of 33 & supero-inferiorly from middle 1/3<sup>rd</sup> of 32, 33 till apical 1/3<sup>rd</sup> of 32 & 33. Evidence of loss of labial cortical plate and thinning of lingual cortical plate. Dimensions of the lesion were, Antero-posteriorly: - 7.3mm, Supero -inferiorly: - 11.1mm & Mesio-distally: - 4.9mm. The internal structure was uniformly radiolucent with no calcifications. Radiographic diagnosis was suggestive of lateral periodontal cyst involving 32 & 33.

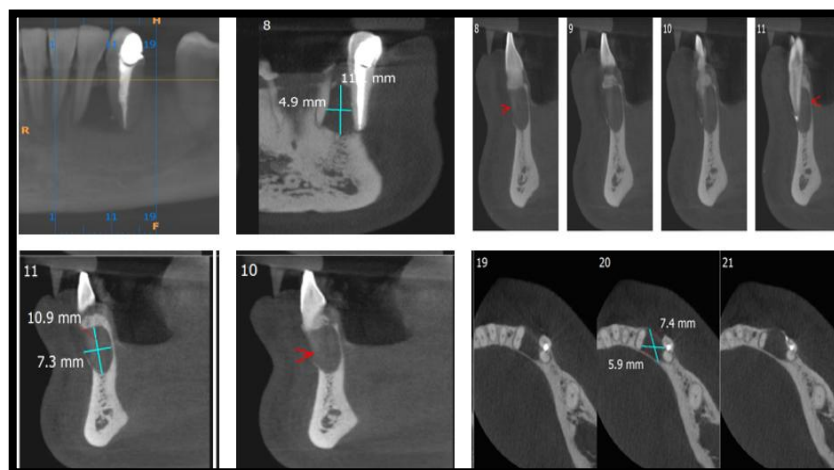


Fig.3-LATERAL PERIODONTAL CYST

## 3. DISCUSSION-

CBCT provides high spatial resolution and a short scan time and rapid image acquisition with less radiation exposure compared to other conventional scans. CBCT scanners are mounted on a revolving gantry which emits from its source a cone-shaped beam of ionizing radiation which then passes through the field of interest and reaches the detector opposite end.<sup>9</sup> Source and detector create sequential, full or partial projection of images according to rotating around the field at the fulcrum. The pictures are obtained and read as a voxel (three-dimensional pixel or volume pixel) for three-dimensional reconstruction.<sup>10</sup> The radiation dose is significantly lower than the radiation dose conventional medical CT scans.<sup>11</sup>



CBCT was used to show extent, boundaries, surrounding structures and intralesional contents of lesions cyst in three dimensions when the lesion overlaps adjacent bone structures. They can also be used for assessment size and outline of pre- or post-operative deformities in tumor resection and assistance in determining bone volume necessary for the reconstruction procedure.<sup>12</sup>

In the reconstructed 3D CBCT images, the morphology and alveolar bone height can be accurately displayed, shows buccolingual thickness, mesiodistal width, clear local bone structures and their anatomical relationship with surrounding structures. These images may be helpful the placement of the implant because they determine the volume bones, position, direction and volume of implants which needs to be placed. 13,14 CBCT is better than the other modalities used in mandibular canal (MC) tracing. MC can be easily visualized by creating a virtual replica with marking the course of the mandibular canal in different location, provides volumetric image rendering, better understanding of localization, cortical destruction, and connections with surrounding anatomical structures. Coronal and sagittal dimensions generated by CBCT shows the relationship of the inferior alveolar nerve bundle and mandibular third molar, allows the surgeon to do so proximity in vertical, lateral and depth dimension. Knowledge of the position neurovascular bundle in relation to surrounding structures is used in treatment planning and its exact location is important for the success of many procedures such as implant placement, tooth extraction or surgical osteotomy.

To avoid damage and complications to the neighboring structures, locations and anatomical variations the maxillofacial structures should be identified in each patient before using appropriate radiographic techniques surgical treatment planning.<sup>2,5</sup>

When evaluating cysts or benign tumors using CT, intraoral or panoramic radiographs show only two dimensions of the lesion. In contrast, it records all three dimensions multiplanar (axial, coronal and sagittal planes) CBCT imaging. They provide such multiplanar views information on the extent of bone resorption, sclerosis, cortical expansion, internal or external calcification and proximity to other vital structures.

CBCT can also be used as an adjuvant for routine panoramic radiographs in the following cases:

1. Canine inclination in the panoramic X-ray exceeding 30°
2. Root resorption of adjacent teeth is suspected, and/or
3. Canine apex is not clearly discernible in the panoramic..<sup>16</sup>

Every application of radiographic technology must be consider with its potential risks and net benefits produces. Before the introduction of CBCT, multiplanar views were obtained mainly using CT (CT) and magnetic resonance imaging (MRI). Physical dimensions and price MDCT and MRI equipment proved impractical for installation in a typical dental office. Smaller physical dimensions, lower costs and easier operation led to rapid adoption. We believe that in suspicious cases cysts and infiltrative tumors or fractures CBCT can be taken directly instead of a panoramic X-ray or CT thereby saving the patient from all unnecessary radiation exposure. CBCT images allow practitioners to better diagnose and understand the true extent of dental disease and therefore may provide more appropriate treatment for patients.

#### 4. CONCLUSION-

CBCT has become an important diagnostic tool for oral administration and maxillofacial surgeons. This image modality can be better utilized by realizing its capacities and limitations. It provides the physician with valuable information and should be used whenever it is beneficial for the patient outweighs the potential risk of radiation. And combination of clinical information, signs, symptoms and X-ray findings should be taken into account for the determination of need for surgery or follow-up.

5. Source of Funding None.

6. Conflict of Interest The authors declare no conflict of interest.

#### References

1. Horner K. Cone-beam computed tomography for oral surgical applications: where is the evidence? *Oral Surg.* 2013;6(3):112–28. doi:10.1111/ors.12052.
2. Hatcher DC, Dial C, Mayorga C. Cone beam CT for pre-surgical assessment of implant sites. *J Calif Dent Assoc.* 2003;31(11):825–33.
3. Kamburoglu K. Use of dentomaxillofacial cone beam computed ~ tomography in dentistry. *World J Radiol.* 2015;7:128–30.
4. Oztunç H, Evlice B, Tatli U, Evlice A. Cone-beam computed tomographic evaluation of styloid process: A retrospective study of 208 patients with orofacial pain. *Head Face Med.* 2014;10:5.
5. Orhan K, Seke BK, Aksoy S, Bayindir H, Berberoglu A, Seker E, et al. ~ Cone beam CT evaluation of maxillary sinus septa prevalence, height, location and morphology in children and an adult population. *Med Princ Pract.* 2013;22(1):47–53.
6. Sinanoglu A, Orhan K, Kursun S, Inceoglu B, Oztas B. Evaluation of optic canal and surrounding structures using cone beam computed tomography: Considerations for maxillofacial surgery. *J Craniofac Surg.* 2016;27:1327–30.
7. Shweel M, Amer I, El-Shamanhory AF. A comparative study of cone-beam CT and multidetector CT in the preoperative assessment of odontogenic cysts and tumors. *Egypt J Radiol Nucl Med.* 2013;44(1):23–32.
8. Nakagawa Y, Kobayashi K, Ishii H, Mishima A, Ishii H, Asada K, et al. Preoperative application of limited cone beam computerized tomography as an assessment tool before minor oral surgery. *Int J Oral Maxillofac Surg.* 2002;31(3):322–6.
9. Ludlow JB, Laster WS, See M, Bailey LJ, Hershey HG. Accuracy of measurements of mandibular anatomy in cone beam computed tomography images. *Oral Surg Oral Med Oral Pathol Oral Radiol Endod.* 2007;103:534–42.
10. Orentlicher G, Abboud M. The use of 3-dimensional imaging in dentoalveolar surgery. *Compendium.* 2011;32:1–7.
11. Loubele M, Assche NV, Carpentier K, Maes F, Jacobs R, Steenberghe DV, et al. Comparative localized linear accuracy of small-field conebeam CT and multislice CT for alveolar bone measurements. *Oral Surg Oral Med Oral Pathol Oral Radiol Endod.* 2008;105(4):512–8.
12. Suomalainen A, Esmaili EP, Robinson S. Dentomaxillofacial imaging with panoramic views and cone beam CT. *Insights Imaging.* 2015;6(1):1–16. doi:10.1007/s13244-014-0379-4.
13. Patel S, Dawood A, Ford TP, Whaites E. The potential applications of cone beam computed tomography in the management of endodontic problems. *Int Endod J.* 2007;40:818–30.



14. Ghaeminia H, Meijer GJ, Soehardi A, Borstlap WA, Mulder J, Berge SJ. Position of the impacted third molar in relation to the mandibular canal. Diagnostic accuracy of cone beam computed tomography compared with panoramic radiography. *Int J Oral Maxillofac Surg.* 2009;38:964–71.
15. Bodin I, Isacsson G, Julin P. Cysts of the nasopalatine duct. *Int J Oral Maxillofac Surg.* 1986;15:696–706.
16. Wriedt S, Jaklin J, Al-Nawas B, Wehrbein H. Impacted upper canines: examination and treatment proposal based on 3D versus 2D diagnosis. *J Orofac Orthop.* 2012;73(1):28–40.
17. Peck JL, Sameshima GT, Miller A, Worth P, Hatcher DC. Mesiodistal root angulation using panoramic and cone beam CT. *Angle Orthod.* 2007;77:206–13.
18. Liu DG, Zhang WL, Zhang ZY, Wu YT, Ma XC. Localization of impacted maxillary canines and observation of adjacent incisor resorption with cone-beam computed tomography. *Oral Surg Oral Med Oral Pathol Oral Radiol Endod.* 2008;105(1):91–8.
19. Walker L, Enciso R, Mah J. Three-dimensional localization of maxillary canines with cone-beam computed tomography. *Am J Orthod Dentofac Orthop.* 2005;128:418–23.