To Study Level of Triglycerides and Other Haematological Findings to Determine the Development and Prevalence of Multi Organ Dysfunction (MODS) In the Patients of Scrub Typhus

[1]Dr. Kushal Jain, [2]Dr. Bansari Prakash Tamboli, [3]Dr. R.K.Samar

[1]3rd year Postgraduate Resident, [2]3rd year Postgraduate Resident, [3]Associate Professor
[1]Department of General Medicine
[1]Pacific Institute of Medical Sciences, Udaipur, India

Abstract: Scrub typhus is an emerging infectious disease in many parts of the world, and is endemic to South Eastern and Far Eastern countries of Asia. Scrub typhus can be a very serious infection that often presents with non-specific symptoms, making it difficult to differentiate from other infections. The laboratory findings and clinical course may also vary significantly, making diagnosis and appropriate treatment difficult. Complications include jaundice, hepatitis, renal failure, ARDS, myocarditis, encephalitis, etc. Here we present a study of scrub typhus in our medical college at the outskirt of Udaipur city in the state of Rajasthan, India during the two year study period from September 2020 to August 2022, a total of 100 cases were included. Emphysis was given on the levels of triglycerides and other haematological findings to determine the development and prevelance of multi organ dysfunction (MODS) in the patients of scrub typhus. Prompt diagnosis and treatment is essential as a delay in treatment can result in significant mortality. From this study, it is concluded that more the levels of triglyceride, more is the development of MODS.

Keywords: Scrub typhus, Orientia tsutsugamushi, triglycerides, multi organ dysfunction (MODS)

I. Introduction

Scrub typhus is an emerging infectious disease in many parts of the world, and is endemic to South Eastern and Far Eastern countries of Asia (India, Sri Lanka, Pakistan, Japan, Thailand and Korea), also extending from Afghanistan down to northern Australia, the so-called Tsutsugamushi triangle.[1] It is an important cause of acute undifferentiated febrile illnesses in the Indian subcontinent. Clinical features include acute onset of fever, headache, myalgia, multiple organ dysfunction and eschar at the site of inoculation, which is present in a variable percentage of patients. It can range in severity from a mild, self-limiting disease to, if untreated, a fatal illness in 30–50% of those it affects such as acute respiratory distress syndrome (ARDS), septic shock and multisystem organ failure concluding in death. It is a chigger mite-borne bacterial infection of humans caused by Orientia tsutsugamushi. Mammalian cells store excess fatty acids in the form of triglycerides within lipid droplets and the intracellular bacterium Orientia tsutsugamush induces the formation of lipid droplets. The pathogen-infection induced the accumulation of triglycerides even without external supply of fatty acids. They caused decreased energy production and deficiencies in both remethylation sources and glutathione. In addition, they accelerated uncommon energy production pathways (i.e., excess fatty acid and protein oxidation) in host body. Infection resulted in splenomegaly with distinct phospholipid and amino acid characteristics.

II. Method

A total of 100 patients were included over 18 years of age with scrub typhus admitted to Pacific Institute of Medical Sciences (PIMS), Udaipur between September 2020 to August 2022, a period of 2 years. Scrub typhus was confirmed by IgM ELISA test. Patients with scrub typhus positive test with or without eschar were included. Patients with past history of chronic renal failure, liver failure, malaria/ dengue/chikungunya/brucellosis positive and patients on dyslipidemic drugs (statins and fibrates) are excluded. A detailed history and clinical examination, including careful search for an eschar, was documented for each patient. Basic laboratory investigations were performed, including complete blood count, renal function test, glucose, liver function test, lipid profile and chest X-rays; additional investigations were performed in some patients including blood culture, quantitative buffy coat test for malarial parasite, abdominal ultrasound and serology for leptospirosis and dengue. Scrub Typhus Detect was used on serum samples for performing IgM ELISA and it was considered positive when optical density (OD) was found >0.5.

The data will be entered in MS Excel software version 17 and analyzed using Statistical Packages for Social Sciences (SPSS). Descriptive data are given as the mean standard deviation (SD) or as the median and range. The quantitative data will be analyzed using Independent Student's T test, Pearson's correlation test, ANOVA test. The associations of clinical and laboratory features with the outcome were analyzed by univariate and multivariate logistic regression and 95% confidence intervals (95% CI) were calculated. A two sided p-value of 0.05 or less was considered statistically significant for all tests.

III. Discussion

Trombiculid mites (such as Leptotrombidium delicense and L. palladium) found in long grasses and in dirt-floor homes are the natural host of the organism, and the disease is transmitted to humans through infected larval stages (chiggers) of the mites during feeding. Most of the cases are from rural area due to favourable environment for the growth of mites. Outbreaks usually occur during rainy season. The incubation period is usually between six to twenty-one days from exposure. The pathophysiological hallmark of scrub typhus is disseminated vasculitis with subsequent vascular injury that involves organs such as skin, liver, brain, kidney, meninges and the lung. In some cases, the pathogens multiply at the site of entry, forming an inflammatory lesion known

as an eschar with regional lymphadenopathy, which is characteristic of the disease. Within a few days, patients develop rickettsemia and causes disseminated intravascular coagulation (DIC) with platelet consumption, vascular leak, pulmonary edema, shock, hepatic dysfunction and meningoencephalitis.[11] The clinical picture is characterized by sudden onset fever with chills, headache, backache and myalgia, profuse sweating, vomiting and enlarged lymph nodes, associated with rash and often an eschar. After five to eight days of fever, a macular or maculopapular rash appears on the trunk and later extend to the arms and legs in few patients.[4] Although the eschar is reported to be less frequently observed in South Asian patients than in East Asian or Caucasians, 55% of patients had an eschar in a recent study from South India.[3,4] In a large retrospective analysis of 418 patients with confirmed scrub typhus and an eschar, a significant difference in the distribution of eschar was noted between males and females. In females, it was mostly seen over the chest and abdomen (42.3%), while in males, it was seen in the axilla, groin and genitalia (55.8%). Unusually eschar were found over the cheek, ear lobe and dorsum of the feet. [5] Laboratory confirmation of scrub typhus is generally by serological methods, with the indirect fluorescent assay being the most commonly used test; paired titres are usually required to make a confirmatory diagnosis. ELISA and passive haemagglutination assay are also available.[1,2] Complications of scrub typhus infection include pneumonia, acute respiratory distress syndrome (ARDS)[6,7,8] myocarditis[9], encephalitis[10], hepatitis[11], DIC[12], hemophagocytic syndrome[13], acute kidney injury[14], acute pancreatitis[15], transient adrenal insufficiency[16], subacute painful thyroiditis[17] and presentation as an acute abdomen.[18] Several neurological manifestations have been observed in the setting of scrub typhus infection. The most common neurological presentation in scrub typhus is as meningitis, meningoencephalitis or encephalitis.[10,19] Others include cerebral venous thrombosis, GuillainBarre Syndrome, transient Parkinsonism and myoclonus, opsoclonus, cerebellitis, transverse myelitis, polyneuropathy, facial palsy, abducens nerve palsy and bilateral optic neuritis. [20-28] Patients with mild disease presenting with fever without organ dysfunction require antipyretics along with antibiotics. Patients presenting with organ dysfunction would need organ support depending on the nature and extent of organ dysfunction.[29] Patients with respiratory failure are supported either by means of non-invasive or invasive mechanical ventilation based on standard criteria in the management of respiratory failure. Those patients in shock are treated by fluids and vasoactive therapy if the blood pressure does not improve with fluids. Renal replacement therapy is required in patients having acute kidney injury with scrub typhus. Those patients with DIC associated with clinical bleeding may require transfusion of blood or blood products depending on the nature of coagulation derangement. Antibiotics used are doxycycline, chloramphenicol, azithromycin, rifampicin, roxithromycin and tetracycline. Conventionally, the treatment of scrub typhus involves the use of the tetracycline group of antibiotics or chloramphenicol. Since these drugs are contraindicated in pregnancy and in children, alternative agents such as quinolones and macrolides are used.[30,31] Doxycycline is the preferred drug in the treatment of scrub typhus. A therapeutic response to doxycycline therapy is used as a diagnostic test.[32] In less sick patients oral doxycycline can be administered at 100 mg twice daily. The duration of treatment is 7 days. In critically ill patients, like those in shock, absorption of enteral doxycycline may be problematic, therefore use of intravenous doxycycline is recommended; if unavailable, intravenous azithromycin can be used alone or in combination with enteral doxycycline[33]. In pregnancy Azithromycin is the recommended drug instead of doxycycline. Rifampicin may be considered in case of doxycycline resistance.[34]

IV. Result

We studied 100 patients with scrub typhus confirmed on the basis of antibody test out of which 84% patients had hypertriglyceridemia. Patients presented with symptoms like fever with chills, nausea, breathlessness, cough, vomiting and generalized body ache. Eschar was present in 22% patients on examination along with organomegaly in few of them. Liver function, renal function, leukocyte count and platelet count were found deranged. 56% patients developed MODS with mortality of 13% patients and it has been found that patients with high levels of triglycerides developed MODS.

Triglyceride levels (mg/dl)	Number of patients	Percentage (%)
<165	16	16
166- 265	9	9
266- 365	35	35
366- 465	18	18
466- 565	9	9
566- 665	6	6
666- 765	4	4
>765	3	3
	100	

Table 1- Number and percentage of patients in different triglyceride level ranges

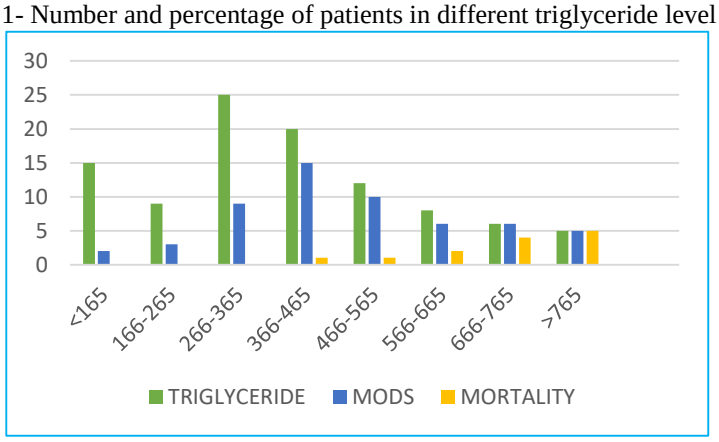

Figure 1- graph showing relation between number of patients in different triglyceride level range, MODS and mortality

Values	Number of patients		Percentage
	Normal range	Deranged	
RFT	48	52	52
LFT	43	57	57
WBC Count	40	60	60
Platelet	46	54	54

Table 2- Number and percentage of patients with normal and deranged range of haematological levels. (RFT- Renal function test, LFT- Liver function test, WBC Count- White Blood Cell count)

V. Conclusion

Scrub typhus can be a very serious infection that often presents with non-specific symptoms, making it difficult to differentiate from other infections. The laboratory findings and clinical course may also vary significantly, making diagnosis and appropriate treatment difficult. Complications include jaundice, hepatitis, renal failure, ARDS, myocarditis, encephalitis, etc. Prompt diagnosis and treatment is essential as a delay in treatment can result in significant mortality. From this study, it is concluded that more the levels of triglyceride, more is the development of MODS.

VI. Reference

1. Rajapakse S, Weeratunga P, Sivayoganathan S, Fernando SD. Clinical manifestations of scrub typhus. Trans R Soc Trop Med Hyg. 2017 Feb 1;111(2):43-54. doi: 10.1093/trstmh/trx017. PMID: 28449088.
2. Peter JV, Sudarsan TI, Prakash JAJ, Varghese GM. Severe scrub typhus infection: Clinical features, diagnostic challenges and management. World J Crit Care Med 2015; 4(3): 244-250 Available from: URL: http://www.wjgnet.com/2220-3141/full/v4/i3/244.htm DOI: http://dx.doi.org/10.5492/wjccm.v4.i3.244
3. Varghese GM, Janardhanan J, Trowbridge P, Peter JV, Prakash JA, Sathyendra S, Thomas K, David TS, Kavitha ML, Abraham OC, Mathai D. Scrub typhus in South India: clinical and laboratory manifestations, genetic variability, and outcome. Int J Infect Dis 2013; 17: e981-e987 [PMID: 23891643 DOI: 10.1016/j.ijid.2013.05.017]
4. Jeong YJ, Kim S, Wook YD, Lee JW, Kim KI, Lee SH. Scrub typhus: clinical, pathologic, and imaging findings. Radiographics 2007; 27: 161-172 [PMID: 17235005 DOI: 10.1148/rg.271065074]
5. Kundavaram AP, Jonathan AJ, Nathaniel SD, Varghese GM. Eschar in scrub typhus: a valuable clue to the diagnosis. J Postgrad Med 2013; 59: 177-178 [PMID: 24029193 DOI: 10.4103/0022-385 9.118033]
6. Im JH, Baek JH, Lee JS, Chung MH, Lee SM, Kang JS. A case series of possibly recrudescent Orientia tsutsugamushi infection presenting as pneumonia. Jpn J Infect Dis 2014; 67: 122-126 [PMID: 24647257]
7. Saxena A, Khiangte B, Tiewsoh I. Scrub typhus complicated by acute respiratory distress syndrome and multiorgan failure; an unrecognized alarming entity in central India: a report of two cases. J Family Med Prim Care 2014; 3: 80-83 [PMID: 24791245 DOI: 10.4103/2249-4863.130334]
8. Varghese GM, Trowbridge P, Janardhanan J, Thomas K, Peter JV, Mathews P, Abraham OC, Kavitha ML. Clinical profile and improving mortality trend of scrub typhus in South India. Int J Infect Dis 2014; 23: 39-43 [PMID: 24661931 DOI: 10.1016/j.ijid.2014.02.009]
9. Sittiwangkul R, Pongprot Y, Silviliarat S, Oberdorfer P, Jittamala P, Sirisanthana V. Acute fulminant myocarditis in scrub typhus. Ann Trop Paediatr 2008; 28: 149-154 [PMID: 18510826 DOI: 10.1179/ 146532808X302189]
10. Kar A, Dhanaraj M, Dedeepiya D, Harikrishna K. Acute encephalitis syndrome following scrub typhus infection. Indian J Crit Care Med 2014; 18: 453-455 [PMID: 25097358 DOI: 10.4103/ 0972-5229.136074]
11. Chung JH, Lim SC, Yun NR, Shin SH, Kim CM, Kim DM. Scrub typhus hepatitis confirmed by immunohistochemical staining. World J Gastroenterol 2012; 18: 5138-5141 [PMID: 23049227 DOI: 10.3748/wjg.v18.i36.5138]
12. Ono Y, Ikegami Y, Tasaki K, Abe M, Tase C. Case of scrub typhus complicated by severe disseminated intravascular coagulation and death. Emerg Med Australas 2012; 24: 577-580 [PMID: 23039302 DOI: 10.1111/j.1742-6723.2012.01600.x]
13. Lin YH, Lin YH, Shi ZY. A case report of scrub typhus-associated hemophagocytic syndrome and a review of literature. Jpn J Infect Dis 2014; 67: 115-117 [PMID: 24647254 DOI: 10.7883/ yoken.67.115]
14. Vikrant S, Dheer SK, Parashar A, Gupta D, Thakur S, Sharma A, Kaushal SS, Kanga A. Scrub typhus associated acute kidney injury - a study from a tertiary care hospital from western Himalayan State of India. Ren Fail 2013; 35: 1338-1343 [PMID: 23952649 DOI: 10.3109 /0886022X.2013.828257]
15. Bhatt A, Menon AA, Bhat R, Gurusiddana SG. Pancreatitis in scrub typhus. J Glob Infect Dis 2014; 6: 28-30 [PMID: 24741228 DOI: 10.4103/0974-777X.127947]
16. Mookkappan S, Basheer A, Chidambaram S, Natarajan N, Shrimanth B. Transient adrenal insufficiency and post-treatment bradycardia in scrub typhus - a case report. Australas Med J 2014; 7: 164-167 [PMID: 24719653 DOI: 10.4066/AMJ.2014.1951]
17. Kim Sh, Park TS, Baek HS, Jin HY. Subacute painful thyroiditis accompanied by scrub typhus infection. Endocrine 2013; 44: 546-548 [PMID: 23564597 DOI: 10.1007/s12020-013-9947-5]
18. Mahajan SK, Babu SN, Sharma D, Singh D, Kanga A, Kaushal SS. Scrub typhus presenting as acute abdomen. Trop Doct 2011; 41: 185-186 [PMID: 21724691 DOI: 10.1258/td.2011.110079]
19. Misra UK, Kalita J, Mani VE. Neurological manifestations of scrub typhus. J Neurol Neurosurg Psychiatry 2015; 86: 761-766 [PMID: 25209416 DOI: 10.1136/jnnp-2014-308722]
20. Jena SS, Mathew A, Sanjith A, Ajith S, Nair BR, Prakash J. Cerebral venous sinus thrombosis presentation in severe scrub typhus infection: a rare entity. Neurol India 2014; 62: 308-310 [PMID: 25033856 DOI: 10.4103/0028-3886.136991]

21. Sawale VM, Upreti S, Singh TS, Singh NB, Singh TB. A rare case of Guillain-Barre syndrome following scrub typhus. Neurol India 2014; 62: 82-83 [PMID: 24608469 DOI: 10.4103/0028-3886.128340]
22. Chiou YH, Yang CJ, Lai TH. Scrub typhus associated with transient parkinsonism and myoclonus. J Clin Neurosci 2013; 20: 182-183 [PMID: 23010430 DOI: 10.1016/j.jocn.2012.01.047]
23. D'sa S, Singh S, Sowmya S. Opsoclonus in scrub typhus. J Postgrad Med 2012; 58: 296-297 [PMID: 23298927 DOI: 10.4103/ 0022-3859.105453]
24. Karanth SS, Gupta A, Prabhu M. Pure cerebellitis due to scrub typhus: a unique case report. Trop Doct 2013; 43: 41-42 [PMID: 23550204 DOI: 10.1177/0049475513480775]
25. Lee KL, Lee JK, Yim YM, Lim OK, Bae KH. Acute transverse myelitis associated with scrub typhus: case report and a review of literatures. Diagn Microbiol Infect Dis 2008; 60: 237-239 [PMID: 17997258 DOI: 10.1016/j.diagmicrobio.2007.09.015]
26. Kim JH, Lee SA, Ahn TB, Yoon SS, Park KC, Chang DI, Chung KC. Polyneuropathy and cerebral infarction complicating scrub typhus. J Clin Neurol 2008; 4: 36-39 [PMID: 19513323 DOI: 10.3988/jcn.2008.4.1.36]
27. Lin WR, Chen TC, Lin CY, Lu PL, Chen YH. Bilateral simultaneous facial palsy following scrub typhus meningitis: a case report and literature review. Kaohsiung J Med Sci 2011; 27: 573-576 [PMID: 22208541 DOI: 10.1016/j.kjms.2011.10.003]
28. Bhardwaj B, Panda P, Revannasiddaiah S, Bhardwaj H. Abducens nerve palsy in a patient with scrub typhus: a case report. Trop Biomed 2013; 30: 706-709 [PMID: 24522141]
29. Griffith M, Peter JV, Karthik G, Ramakrishna K, Prakash JA, Kalki RC, Varghese GM, Chrispal A, Pichamuthu K, Iyyadurai R, Abraham OC. Profile of organ dysfunction and predictors of mortality in severe scrub typhus infection requiring intensive care admission. Indian J Crit Care Med 2014; 18: 497-502 [PMID: 25136187 DOI: 10.4103/0972-5229.138145]
30. Fang Y, Huang Z, Tu C, Zhang L, Ye D, Zhu BP. Metaanalysis of drug treatment for scrub typhus in Asia. Intern Med 2012; 51: 2313-2320 [PMID: 22975540 DOI: 10.2169/internalmedicine.51.7816]
31. Song JH, Lee C, Chang WH, Choi SW, Choi JE, Kim YS, Cho SR, Ryu J, Pai CH. Short-course doxycycline treatment versus conventional tetracycline therapy for scrub typhus: a multicenter randomized trial. Clin Infect Dis 1995; 21: 506-510 [PMID: 8527534 DOI: 10.1093/clinids/21.3.506]
32. Chrispal A, Boorugu H, Gopinath KG, Chandy S, Prakash JA, Thomas EM, Abraham AM, Abraham OC, Thomas K. Acute undifferentiated febrile illness in adult hospitalized patients: the disease spectrum and diagnostic predictors - an experience from a tertiary care hospital in South India. Trop Doct 2010; 40: 230-234 [PMID: 20870680 DOI: 10.1258/td.2010.100132]
33. Peter JV, Karthik G, Ramakrishna K, Griffith MF, Jude Prakash JA, Job V, Chacko B, Graham PL. Elevated procalcitonin is associated with increased mortality in patients with scrub typhus infection needing intensive care admission. Indian J Crit Care Med 2013; 17: 174-177 [PMID: 24082615 DOI: 10.4103/0972-5229.117063]
34. Rajapakse S, Rodrigo C, Fernando SD. Drug treatment of scrub typhus. Trop Doct 2011; 41: 1-4 [PMID: 21172901 DOI: 10.1258/ td.2010.100311]