

Imaging Spectrum of Fungal Pulmonary Infections.

¹chinimilli Sriharika, ²p. Sirisha Naidu, ³sandhya Jarabhala, ⁴ch. Madhavi

¹post Graduate In Md Radio-Diagnosis, ²assistant Professor, Md Radiodiagnosis

³Post Graduate In Md Radio-Diagnosis, Md Radio-Diagnosis, ⁴professor, Md Radiodiagnosis.

¹department Of Radiodiagnosis,

¹maharajah's Institute Of Medical Sciences, Nellimarla, Vizianagaram, Andhra Pradesh, India

Abstract: Pulmonary fungal infections, which can be opportunistic or endemic, are responsible for considerable mortality and morbidity. Radiologic interpretation along with the patient's clinical presentation, immune status, and history of previous infections can help in reaching an accurate diagnosis. Imaging reveals a consistent pattern of presentation for a specific infection but more often than not there is a significant overlap between various differentials. In this article we discuss various presentations of fungal pulmonary infections with examples of certain classical signs and patterns.

Index Terms: fungal infections, pulmonary infections, HRCT, radiology.

I. INTRODUCTION:

Pulmonary fungal infections, which can be opportunistic or endemic, are responsible for considerable mortality and morbidity. Radiologic interpretation along with the patient's clinical presentation, immune status, and history of previous infections can help in reaching an accurate diagnosis^{[1][2]}. Imaging reveals a consistent pattern of presentation for a specific infection but more often than not there is a significant overlap between various differentials. The human respiratory system is frequently the site of first contact with environmental fungal and fungal-like antigens owing to their ubiquity in nature. Populations at high risk for pulmonary fungal infections include individuals with solid organ or hematological malignancies, those undergoing organ or bone marrow transplantation, Diabetes mellitus and HIV-infected patients. Others who are at intermediate risk include patients on chronic corticosteroid or immunosuppressive therapy, those with pulmonary tubercular infections, chronic kidney disease, chronic obstructive pulmonary disease (COPD), and liver cirrhosis^[1]. In this subgroup of individuals, an aggressive etiological investigation protocol is necessary, because a diagnostic delay increases mortality, and early use of computed tomography in diagnostic protocols is recommended.

II. AIMS & OBJECTIVES

To review various imaging manifestations of fungal pulmonary infections and assess their diagnostic accuracy.

III. Materials & Methods

In this cross-sectional study undertaken in a tertiary health care center, patients with significant pulmonary complaints were evaluated from April 2021 to November 2021 (7 months). A routine tomographic evaluation revealed features consistent with pulmonary infection of fungal etiology in 22 of these patients.

Inclusion criteria:

- Patients are of adult age group with clinically significant pulmonary symptoms like chronic cough, hemoptysis, low grade fever, weight loss etc. and clinic laboratory features indicative of fungal etiology.

Exclusion criteria:

- Pregnancy
- H/o allergy to IVCM
- Inconclusive laboratory findings.

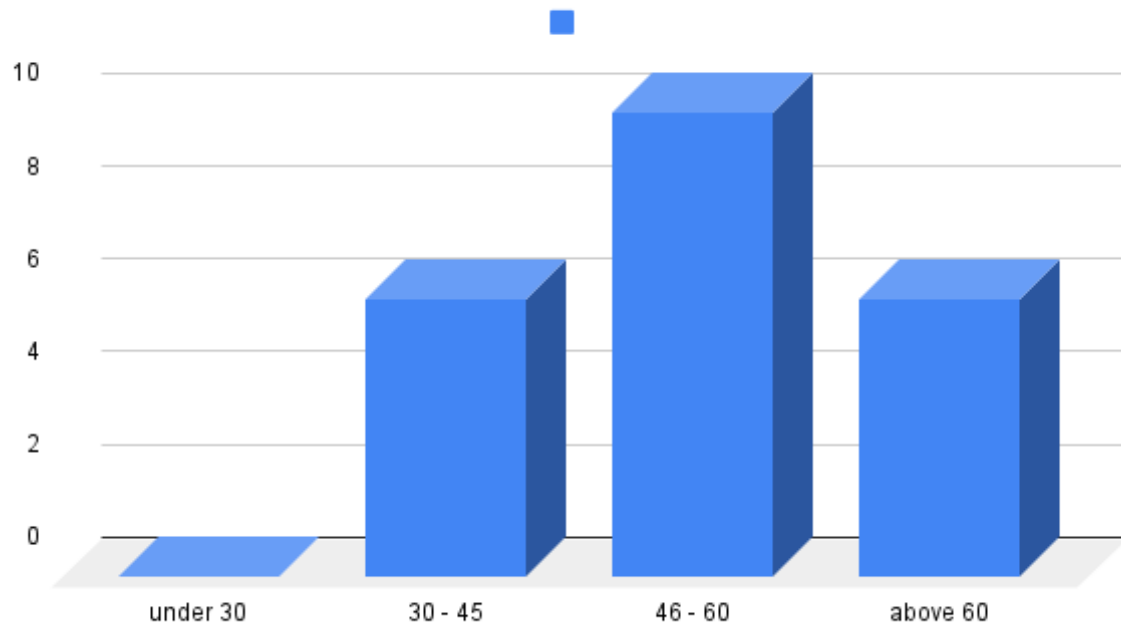
IV. Results

There were 12 males and 10 females in the study, ranging from 42 to 72 years with a mean age at presentation of 54 years.

Out of 22 cases, 15 (68%) revealed features suggestive of Aspergilloma. 2 (9%) cases showed features suggestive of Allergic bronchopulmonary aspergillosis, 3 (13%) cases presented with clinico-radiologic features suggestive of pulmonary mucormycosis. Follow-up confirmed the radiologic diagnosis. Death occurred in 2 (9%) cases in the follow-up period.

The most common presenting features were chronic cough with mucoid or blood-tinged expectoration. Many presented with a history of the completed antibiotic course of ATT for pulmonary tubercular infection. One case was previously diagnosed with asthma and 2 cases revealed features of active tubercular infection later confirmed on sputum examination. COPD was a significant issue in 5 of 22 cases. Extrapulmonary disorders complicating patient health identified during this study were Type 2 diabetes in 6 of 22 cases and chronic kidney disease in a single case.

AGE-WISE DISTRIBUTION



Graph 1: Age at presentation

Symptoms	n = 22	
shortness of breath	18	81%
chronic cough	20	90%
hemoptysis	12	54%
chest tightness	8	36%
weight loss	12	54%
generalized weakness	17	77%

Table 1: Common presenting complaints of the patient

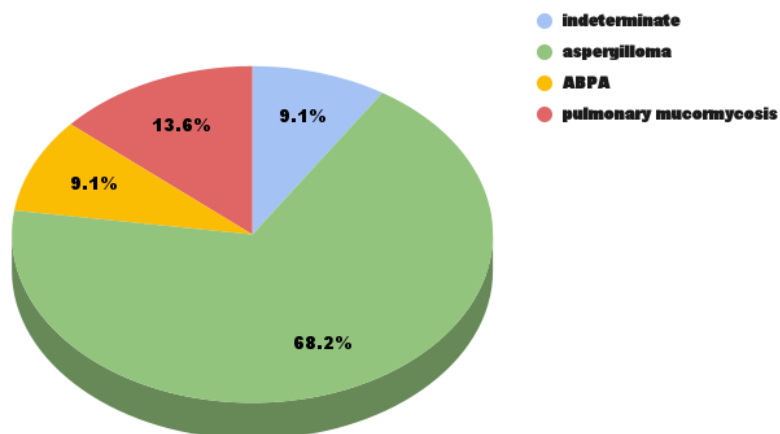
Past history	n=22	
no significant past history	3	13.60%
H/o COVID 19 infection	3	13.60%
H/o PTB - completed ATT	7	31.80%
Active PTB	4	18.20%
k/c/o Bronchial asthma	1	4.10%
COPD	4	18.20%

Table 2: Significant history.

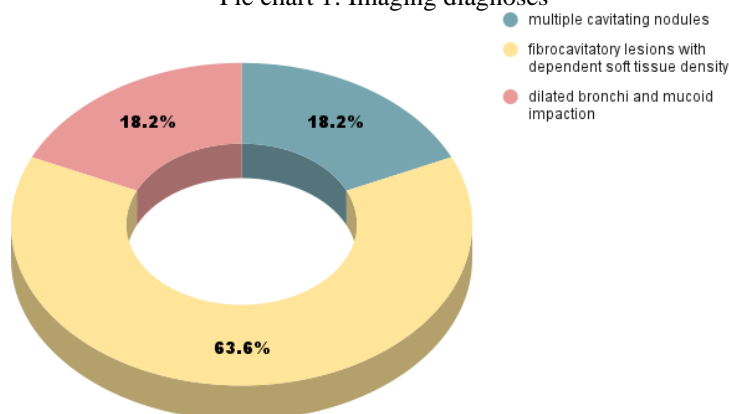
The imaging features identified in this study are:

Bronchiectasis (98%), fibrosis (98%), nodules and cavitations (86%), volume loss (80%), centrilobular nodules with tree-in-bud opacities (28%), consolidation with air bronchogram (18%), ground glass opacities (36%), pleural effusion (9%) and mediastinal lymphadenopathy (50%).^{[3][4][5]}

The common imaging findings are - multiple fibro cavitory lesions with dependent soft tissue densities; patchy areas of fibrosis with multiple round to oval nodules in various stages of cavitation; tubular, varicoid bronchiectatic changes with mucus plugs.

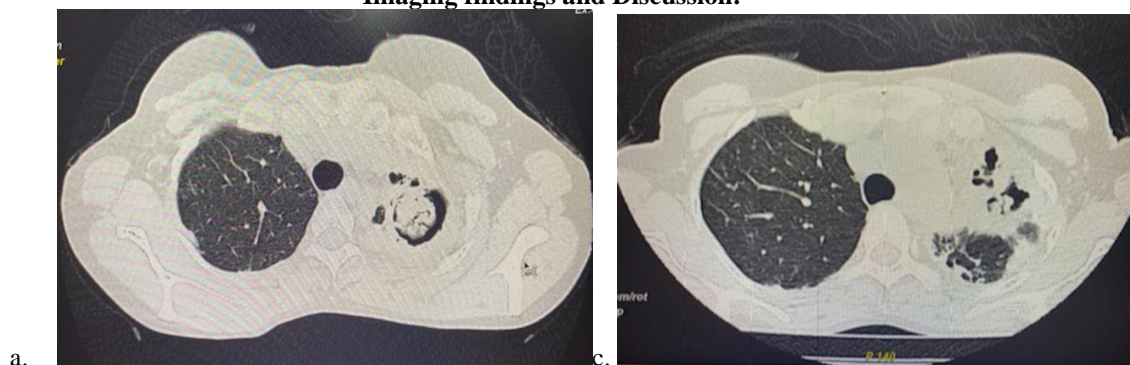


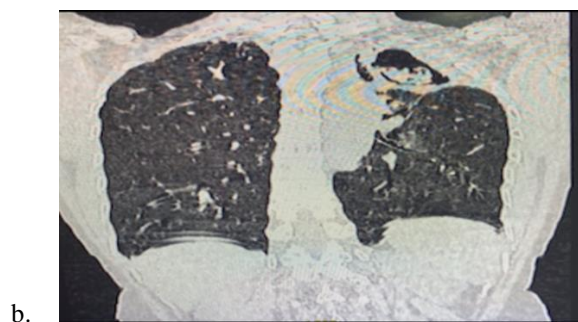Pie chart 1: Imaging diagnoses



Pie chart 2 : Most consistent findings

Imaging findings and Discussion:



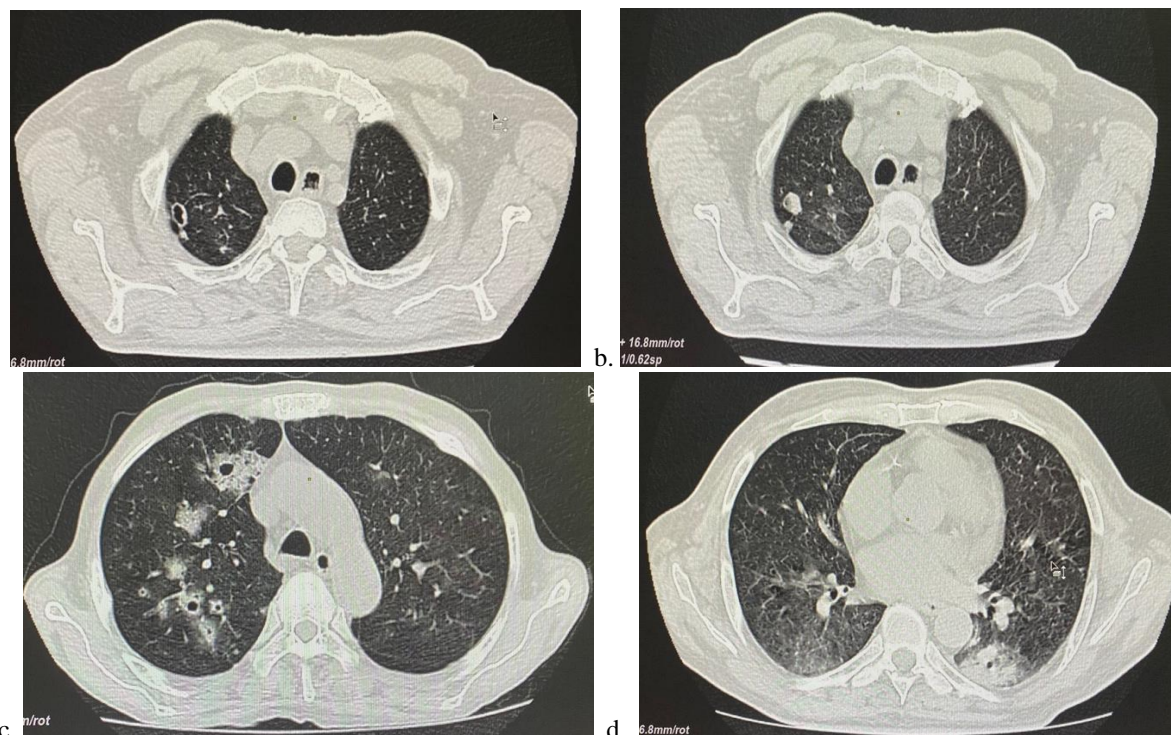


Figures A to C show axial section (in lung window) of NCCT of chest in a patient with chronic cough, hemoptysis, and shortness of breath.

Characteristic Monod sign - a crescent of air around a freely mobile soft tissue density.

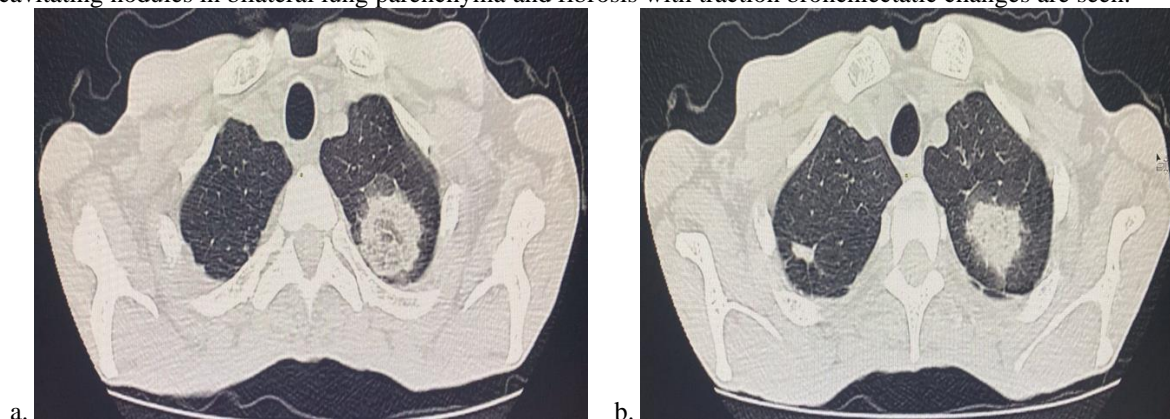
Image C is taken in prone position which emphasizes the mobile nature of the soft tissue density. Image b.- Sagittal section to clearly visualized the fibrocavitary lesion.

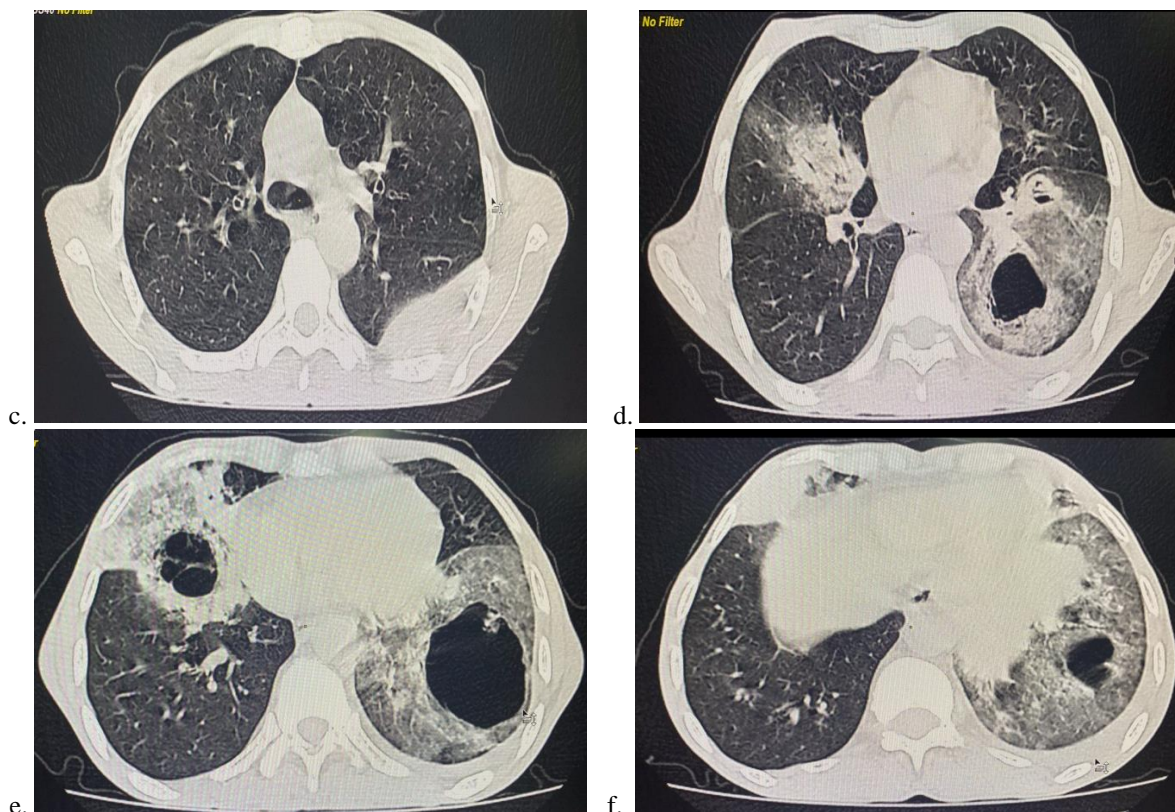
Note fibrosis with traction bronchiectatic changes in multiple lung segments.



Figures A to D : sequential axial sections of NCCT Chest in lung window of a patient presenting with chronic cough with expectoration and low-grade fever.

Multiple cavitating nodules in bilateral lung parenchyma and fibrosis with traction bronchiectatic changes are seen.



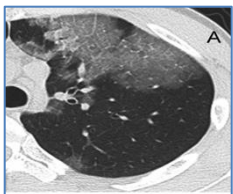
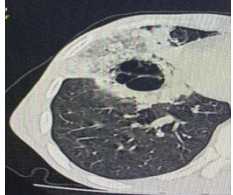
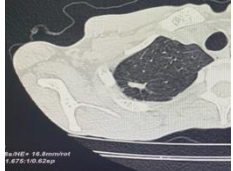

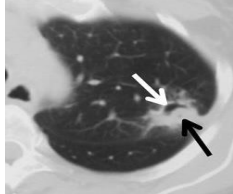
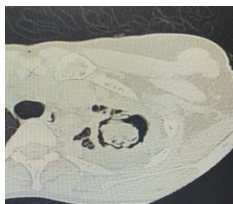


Figures A to F : sequential axial sections of NCCT scan in lung and mediastinal windows of a patient diagnosed with Pulmonary Mucormycosis. 55/M presented with a h/o recent COVID-19 infection. A known diabetic, he came with elevated blood sugars. Sections of abdomen (not shown here) also revealed pancreatic atrophy and calcifications representing chronic calcific pancreatitis. Consolidation with GGO; Nodule in upper lobe; CT halo sign; Left sided pleural effusion are seen.

Conventional X-rays are the first modality of choice in the evaluation of pneumonia. The role of CT comes much later in diagnosis when the patient shows a poor response to standard therapy, indicated by the persistence/progression of symptoms. The clinician then requires help in understanding and characterizing underlying chronic lung disease, complex cases of pneumonia, and identifying complications. Fungi causing pneumonia can be of two types: either pathogenic, which can infect anyone (coccidiomycosis, blastomycosis, histoplasmosis), or saprophytic, which infects immunocompromised people (pneumocystis, candidiasis, aspergillosis, mucormycosis)

Aspergillus fumigatus is ubiquitous- found in soil, decaying vegetation, and dust. Exposure to the fungus is through the respiratory tract but the disease does not typically manifest unless it encounters weakened lungs or an impaired immune system. Its pulmonary manifestations are of five types: simple aspergilloma, allergic bronchopulmonary aspergillosis (ABPA), airway invasive pulmonary aspergillosis, angioinvasive pulmonary aspergillosis, and chronic pulmonary aspergillosis^{[5][6][7]}. Pulmonary mucormycosis (PM) is an uncommon fungal infection most often seen in immunocompromised patients. The fungus grows on decaying food, soil, and animal excrement. Patients usually become infected by inhalation of spores. The most common risk factors include diabetes mellitus, hematologic malignancy, and solid organ or stem cell transplant. The recent advent of COVID-19 infection and subsequent CST, immunosuppression have caused a spike in these cases. PM can have a nonspecific appearance at imaging. For example, early imaging may show peribronchial ground-glass opacity. Later, the disease progresses to consolidation, nodules, and/or masses.

	<p>Consolidation^[8]: Airspace consolidations may be seen in various fungal infections. They are frequently described as part of the semi-invasive, airway-invasive, and bronchopulmonary allergic manifestations of aspergillosis</p>
	<p>Bronchiectasis: Bronchiectasis is defined as a chronic inflammatory bronchial disease with irreversible dilation of the bronchial lumen, and it can occur for several reasons. The various species of the <i>Aspergillus</i> spp. genus are the most prevalent filamentous fungi found in bronchiectasis patients.^[8]</p>

	<p>Ground Glass opacities: indicates intra-alveolar accumulation of fibrin, debris, and microorganisms. These changes are rare in fungal infections but are useful ancillary findings. When associated with consolidations characteristic named signs like Halo and Reversed Halo signs are diagnostic of fungal pneumonia. [6][8]</p>
	<ul style="list-style-type: none"> • Halo sign: Ground glass attenuation surrounding a nodule. [9][10] <p>Reversed halo sign (Bird's nest sign) : Focal Ground glass opacity surrounded by a full or partial ring of consolidation, seen in pulmonary mucormycosis, angioinvasive aspergillosis, cryptogenic organizing pneumonia, tuberculosis, etc.</p>
	<p>Nodules: Multiple nodules that are predominantly peripheral, especially when accompanied by a ground-glass halo, are typical. the nodules progress to central necrosis and cavitation, with the appearance of air within the lesions, known as the "air crescent" sign. Mobile nodules within the lung cavitation are also characteristic of the saprophytic presentation of aspergillosis. Nodules with or without cavitation, as well as centrilobular nodular opacities may be seen</p>
	<p>Cavities : Cavitory lesions can be observed in various fungal infections, such as angioinvasive disease (aspergillosis, mucormycosis, and candidiasis), as well as in the semi-invasive (necrotizing) and saprophytic manifestations of aspergillosis</p>
	<p>Mucus plugs and dilated bronchioles: central (segmental and subsegmental) bronchiectasis, especially in the upper lung fields, together with mucoid impaction. A striking feature of invasive aspergillosis, where increased mucoid secretions with impaired mucociliary clearance produce mucus impaction. Seen in Allergic bronchopulmonary aspergillosis</p>
	<ul style="list-style-type: none"> • Air crescent sign: seen in recovering angioinvasive aspergillosis. It represents a partial or complete crescent of air around central nodularity. • Monod sign: represents a rim of air around freely mobile mass - mycetoma in a pre-existing pulmonary cavity.

Aspergilloma: An Aspergilloma is a type of mycetoma or "fungus ball" usually caused by a saprophytic (non-invasive) colonization by *A. fumigatus*. Aspergillomas are encountered in patients with pre-existing lung damage, most commonly cavities from prior tuberculosis or sarcoidosis.

ABPA: Allergic Bronchopulmonary aspergillosis (ABPA) is a hypersensitivity reaction to *Aspergillus*. Findings represent central bronchiectasis with mucoid impaction classically described as the "finger in glove sign".

Invasive aspergillosis: Invasive aspergillosis is seen in the setting of profound immunosuppression, especially neutropenia. Airway invasive or Angio invasive. Airway thickening, secretions, peribronchial consolidation (large airway involvement), and centrilobular tree-in-bud nodules (small airway involvement) are often seen. The classic CT finding of angioinvasive aspergillosis is the "halo-sign" which is characterized by nodules and areas of nodular consolidation with surrounding ground glass opacity

Mucormycosis: The advent of COVID-19 disease and concomitant use of immunosuppressant drugs led to an increase in the incidence of PM. In early PM, initial CT may simply show a perivascular ground-glass lesion before the development of more extensive imaging findings. Ground-glass lesions usually progress to consolidation, nodules, or masses. Because of the angioinvasive nature of the disease, pulmonary necrosis is common. While most fungal pneumonia shows nonspecific signs at imaging, the reverse halo sign is a specific sign of mucormycosis, occurring in 19%-94% of patients. [10]

Close differentials:

Septic emboli: Microorganisms causing thrombosis in the peripheral pulmonary capillaries. Immunosuppressed patients, patients with arterial or intravenous catheters, intravenous drug abusers, alcoholics, and patients with endocarditis or those undergoing dental

surgery are susceptible to septic emboli. The thrombi lead to infarction and consequent micro-abscesses. The nodules develop rapidly into cavities (within days). Dynamic development helps differentiate it from malignancies.

Distant metastases: Pulmonary metastasis from squamous cell carcinomas, mainly from the gastrointestinal tract and breast, sarcomas, and adenocarcinomas frequently cavitate. On imaging, differentiating malignant tumors from other cavity entities may be difficult, but the clinical history of weight loss and lack of acute symptoms such as fever may be helpful.

Conclusion

Imaging plays an important role in identifying diagnostic features of various fungal infections. Although a significant overlap exists in the imaging spectrum of different etiologies, identifying certain signs can help narrow down diagnosis and optimise patient care. The more times a feature is associated with a disease the greater its positive correlation and diagnostic accuracy. Therefore it is important for the radiologist to know about certain consistent findings for precise diagnosis.

REFERENCES

1. Wanaporn Burivong, Thanatorn Sricharoen, Apichart Thachang, Sunsiree Soodchuen, Panitpong Maroongroge, Vichit Leelasithorn, "Early Radiologic Diagnosis of Pulmonary Infection in Febrile Neutropenic Patients: A Comparison of Serial Chest Radiography and Single CT Chest", *Radiology Research and Practice*, vol. 2021, Article ID 8691363, 7 pages, 2021.
2. Franquet T., Chung J.H. (2019) Imaging of Pulmonary Infection. In: Hodler J., Kubik-Huch R., von Schulthess G. (eds) *Diseases of the Chest, Breast, Heart and Vessels 2019-2022*. IDKD Springer Series. Springer, Cham.
3. Mandeep Garg, Nidhi Prabhakar, Ajay Gulati, Ritesh Agarwal, and Sahajal Dhooria. Spectrum of imaging findings in pulmonary infections. Part 2: Fungal, mycobacterial, and parasitic *Pol J Radiol*. 2019; 84: e214–e223.
4. Torres, Pedro Paulo Teixeira e Silva et al. Tomographic assessment of thoracic fungal diseases: a pattern and signs approach. *Radiologia Brasileira* [online]. 2018, v. 51, n. 5, pp. 313-321.
5. Sudheesh Raveendran, Zhiyan Lu, CT findings and differential diagnosis in adults with invasive pulmonary aspergillosis, *Radiology of Infectious Diseases*, Volume 5, Issue 1, 2018, Pages 14 -25, ISSN 2352-6211,
6. Hilary L. P. Orlowski, Sebastian McWilliams, Vincent M. Mellnick, Sanjeev Bhalla, Meghan G. Lubner, Perry J. Pickhardt, and Christine O. Menias; Imaging Spectrum of Invasive Fungal and Fungal-like Infections *RadioGraphics* 2017 37:4, 1119-1134
7. Prasad Panse, Maxwell Smith, Kristopher Cummings, Eric Jensen, Michael Gotway, Clinton Jokerst, The many faces of pulmonary aspergillosis: Imaging findings with pathologic correlation, *Radiology of Infectious Diseases*, Volume 3, Issue 4, 2016, Pages 192-200, ISSN 2352-6211,
8. Christopher M. Walker, Gerald F. Abbott, Reginald E. Greene, Jo-Anne O. Shepard, Dharshan Vummidi, and Subba R. Digumarthy; Imaging Pulmonary Infection: Classic Signs and Patterns. *American Journal of Roentgenology* 2014 202:3, 479-492
9. Chong, Semin et al.; Pulmonary fungal infection: Imaging findings in immunocompetent and immunocompromised patients; *European Journal of Radiology*, Volume 59, Issue 3, 371 – 383
10. Hisham Wahba, Mylene T. Truong, Xiudong Lei, Dimitrios P. Kontoyiannis, Edith M. Marom, Reversed Halo Sign in Invasive Pulmonary Fungal Infections, *Clinical Infectious Diseases*, Volume 46, Issue 11, 1 June 2008, Pages 1733–1737