

Role of transvaginal ultrasound in diagnosis of female infertility

¹ Vandana Mourya, ² Mukesh Prasad Kushwaha, ³ Anupama, Sharma, ⁴ Himanshu Shah

^{1,2}Consultant Lecture, ^{3,4}Consultant

¹ Department of Radiology, National Medical College, Birgunj, Nepal

² Department of Orthopaedics and trauma Surgery, National Medical College, Birgunj, Nepal

³ Department of Obstetrics and Gynecology, Miteri Hospital, Dang, Nepal

⁴ Department of Orthopaedics and trauma Surgery, Miteri Hospital, Dang, Nepal

Abstract- Infertility is defined as failure to conceive a desired pregnancy after 12 months of unprotected intercourse. Approximately 10% of married couples are infertile. Males and females are equally affected.

Ultrasound is a useful and first line investigation tool available to assess the causes of female infertility and to institute some of the treatments used to ameliorate infertility. Ultrasound is an effective, safe, inexpensive, radiation free, non-invasive tool, readily available, easy to use and easily repeatable approach to evaluate female infertility worldwide. It improves the quality of care provided in female infertility workup by facilitating rapid diagnosis and the visualization of changes in female reproductive physiology required to direct therapy. Ultrasound is the most widely used method of imaging in gynecology and has revolutionized the management of female infertility worldwide.

Aims and Objectives:

1. To study the normal pelvic organ anatomy.
2. To study the various uterine, ovarian and tubal causes in patients presented with infertility and menstrual irregularity.

Methodology:

This is a prospective observational study was conducted in Department of radiology, National Medical College & teaching Hospital, Birgunj, Parsa Nepal for the 6-month duration in the patients presented with the primary or secondary subfertility (Infertility). Patients included in this was of reproductive age group 21 years to 40 years with ethical clearance from the Institutional Review Committee of National Medical College and after obtaining informed consent of the patient.

Ultrasound Assessment: All ultrasound assessments were performed using the same machine Logiq P7 with transabdominal approach by 4 MHz transducer and transvaginal approach by 8MHz TVS transducer.

Data processing and analysis was done by using SPSS version 26 and statistical tests applied are count, percentage, mean, median and standard deviation. Findings was presented as table, bar diagrams and pie-charts.

Result

Ultrasonography (USG) (mainly transvaginal/endovaginal) It is the first-line investigation. It is readily available, inexpensive, noninvasive, radiation-free, relatively less time consuming, and easily repeatable. USG helps in determining the morphology of the uterus and ovaries, uterine and ovarian perfusion, and endometrial thickness, volume, and vascularity. In our study 44 cases included in 6 month of duration of study who presented with menstrual irregularity, amenorrhea, dysmenorrhea, menorrhagia with infertility in the reproductive age group of 21-40 years. Most commonly cases seen in 26-30 years followed by 21-25 years of age group. Both primary and secondary infertility seen.

Conclusion

Evaluation of infertility is impossible without ultrasound assessment. This tool helps all radiologist to examine the pelvic organs (ovaries, uterus, fallopian tube, peritoneal cavity) and is used to prediction of ovulation, endometrial receptivity and many disorders that may affect infertility

Key Words: Transvaginal Ultrasound (TVS), Infertility, Menstrual abnormality, Uterine cause, Ovarian cause PID and Space occupying lesion.

Correspondence:

Dr. Vandana Mourya, Department of Radiology
National Medical college, Birgunj, Parsa, Nepal

INTRODUCTION

Infertility is defined as failure to conceive a desired pregnancy after 12 months of unprotected intercourse(1). Approximately 10% of married couples are infertile. Males and females are equally affected.

Ultrasound is a useful and first line investigation tool available to assess the causes of female infertility and to institute some of the treatments used to ameliorate infertility. Ultrasound is an effective, safe, inexpensive, radiation free, non-invasive tool, readily available, easy to use and easily repeatable approach to evaluate female infertility worldwide. It improves the quality of care provided in female infertility workup by facilitating rapid diagnosis and the visualization of changes in female reproductive physiology required to direct therapy. (2, 3).

Ultrasound is the most widely used method of imaging in gynecology and has revolutionized the management of female infertility worldwide (2).

Ultrasonographic limitations include limited field of view, subjective errors, interference by obesity or by gaseous bowel loops, suboptimal visualization of fallopian tubes and broad ligament, failure to delineate small ovaries, and inability to obtain images in the surgical plane(3, 4).

USG helps in determining the morphology of the uterus and ovaries, uterine and ovarian perfusion, and endometrial thickness, volume, and vascularity. It detects pathological lesions, including tubal lesions and abnormalities of follicular maturation and ovulation. Tubal patency can be confirmed through sonosalpingography. USG can guide oocyte retrieval and embryo transfer in vitro fertilization procedures and drainage of pelvic collections or cystic lesions(5, 6).

Endometrial Evaluation: Endometrial thickness is maximum distance between the echogenic interfaces of myometrium and endometrium in two opposite site measured in the plane through the central longitudinal axis of the uterine body (7).

The endometrium grows 0.5 mm/day in the proliferative phase and 0.1 mm/day in the luteal phase. If endometrial thickness is more than 7 mm in the preovulatory period, the probability of pregnancy is higher(8).

Causes of Infertility:

The causes of female infertility can be broadly categorized into the following:

Uterine causes – Congenital anomalies, infections, uterine synechiae, focal lesions (Fibroid , polyp), intrauterine scar, cervical stenosis, reduced uterine perfusion, and alterations in endometrial thickness and vascularity(1).

Congenital uterine anomalies (Müllerian duct anomalies)

These are considered as causes of infertility when all other causes have been excluded. These are classified according to the American Fertility Society criteria as follows (9):

- Class I or uterine hypoplasia or agenesis
- Class II or unicornuate uterus: A banana-shaped uterus with a single fallopian tube. A rudimentary horn (communicating or non-communicating) may be present
- Class III or uterus didelphys: Two complete uteruses, each with its own cervix. A sagittal vaginal septum is seen in the majority of cases.
- Class IV or bicornuate uterus: Two uterine cavities with one cervix. MRI shows widely separated uterine horns with an intercornual distance of >4 cm and concavity of the fundal contour or an external fundal cleft of >1 cm in depth (10)
- Class V or septate uterus: A fibrous septum is seen that appears hypointense on T2W images while the muscular septum appears intermediate in intensity. MRI criteria includes a convex or flat external fundal contour or external fundal cleft of <1 cm in depth(11).
- Class VI or arcuate uterus: It is a normal variant and is characterized by an external convex contour of the fundus with fundal endometrial indentation.
- Class VII or diethylbestrol-induced: Exposure to this synthetic estrogen antenatally can result in a T-shaped, hypoplastic, and constricted uterus.

Ovarian causes – Follicular and ovulation abnormalities, stromal vascularity, and endometriosis. In PCOS, the ovaries are large (> 10 cc) with 10 or more peripheral follicles with size of 2 to 9 mm in diameter. The stroma in these ovaries is increased (> 25% of the cross-sectional area) and echogenic(12)

Tubal causes – Infections, obstruction (4).

Rationale of study:

The aim of this study is use of vaginal sonography in study of infertile women, including uterus evaluation with more details: Assessment of receptivity of endometrium, endometrial polyp, uterine myoma, adenomyosis, intrauterine adhesion and anatomical abnormalities. Furthermore, the evaluation of ovaries and disorders that affect fertility, such as polycystic ovary, endometrioma, will be explained. In addition, ultrasonographic details of pseudo cyst and hydrosalpinx are described

Review of literature

Transvaginal ultrasonography has provided new anatomic and pathophysiologic information about the female pelvis. Because of probe proximity to the organ of interest and higher insonating frequency, resolution is dramatically improved. Problems previously encountered during transabdominal scanning, such as obesity, bowel gas, and a retroverted uterus, no longer preclude accurate diagnosis. Patient acceptance is nearly universal. Physiologic information concerning the endometrium and ovarian follicles has improved infertility diagnosis and treatment. Hormonal and vascular Doppler changes can be correlated with cyclic endometrial patterns and follicle size (13).

The ultrasound of the female pelvis and the morphologic changes in the uterus and ovaries in relation to the menstrual cycle was described by Kratochwil et al in 1972 (14).

In 1977 Hackerloer et al demonstrated the linear relation between follicular growth and serum concentration of oestradiol in the spontaneous menstrual cycle (15).

Adenomyosis was initially described in 1860 by Rokitansky as fibrous tumors containing gland-like structures that resemble endometrial glands (16).

In 1920, Thomas Cullen (15) published a preliminary report on adenomyoma uteri diffusum benignum and on the distribution of adenomyomas containing uterine mucosa. He suggested that diffuse adenomyoma was the result of basal endometrial invasion and that an encapsulated variety was possibly of müllerian origin (17).

Aims and Objectives:

1. To study the normal pelvic organ anatomy.
2. To study the various uterine, ovarian and tubal causes of infertility

Methodology:

This is a prospective observational study will be conducted in Department of radiology, National Medical College & teaching Hospital, Birgunj, Parsa Nepal for the 1 year duration in the patients presented with the primary or secondary subfertility (Infertility). Patients included in this will be of reproductive age group 18 years to 35 years with ethical clearance from the Institutional Review Committee of National Medical College and after obtaining informed consent of the patient.

Ultrasound Assessment:

All ultrasound assessments were performed using the same machine Logiq P7 with transabdominal approach by 4 MHz transducer and transvaginal approach by 8MHz TVS transducer.

In supine position, transabdominal ultrasound was first performed in full bladder. Once completed, the patient will be asked to empty their bladder and then transvaginal ultrasound will be performed by using sterile TVS probe. The transvaginal transducer was inserted, with special attention being made to the orientation of the image. The probe was placed in the distal vagina or against the external cervical os. Changing the depth of the ultrasound probe created a different focal point and thus bring different areas within view. Sagittal imaging was obtained with side-to-side movements of the probe, from one adnexa (ovary) to the other. Turning the probe to 90° will give us a transverse/semi-coronal orientation. The cervix, internal os, endocervical canal, and the external os was imaged in both sagittal (long-axis) and transverse (short-axis) orientations if required. The length of the uterus was measured in sagittal orientation, from the fundus to the external cervical os if able to image. Transverse/semi-coronal images were also obtained with anteroposterior and transverse diameters measured. Volume was calculated from these values. The endometrium, also referred to as the endometrial stripe, was delineated by its normal echogenic nature, surrounded by the hypoechoic uterine myometrium. The thickest portion on true sagittal imaging was measured. The bilateral ovaries were measured in three dimensions with the calculation of the volumes. Dynamic imaging was performed by a radiologist via placing a hand over the lower abdomen, palpating, and observing the mobility of the internal organs in real time. "Slide sign" when the organs move relatively freely against one another. When they are more fixed during palpation, this is indicative of adhesions (18).

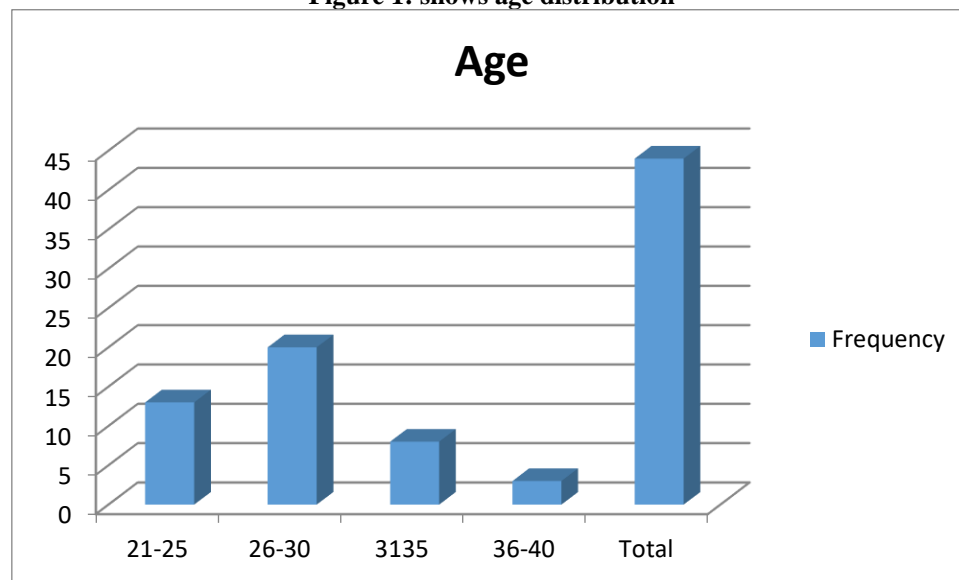
Data processing and analysis was done by using SPSS version 26 and statistical tests applied are count, percentage, mean, median and standard deviation. Findings were presented as table, bar diagrams and pie-charts.

Result

In our study 44 cases included in 6 month of duration of study who presented with menstrual irregularity, amenorrhea, dysmenorrhea, menorrhagia with infertility in the reproductive age group of 21-40 years. Most commonly cases seen in 26-30 years followed by 21-25 years of age group. Both primary and secondary infertility seen.

Table 1: Age distribution

Age	Frequency	Percentage (%)
21-25	13	29.5
26-30	20	45.5
31-35	8	18.2
36-40	3	6.8
Total	44	100.0

Figure 1: shows age distribution

Above table and figure shows age distribution patients presented with infertility. Most common age group is 26-30 years which includes 20 cases, 45.5 % cases of total followed by 21-25 years (29.5%).

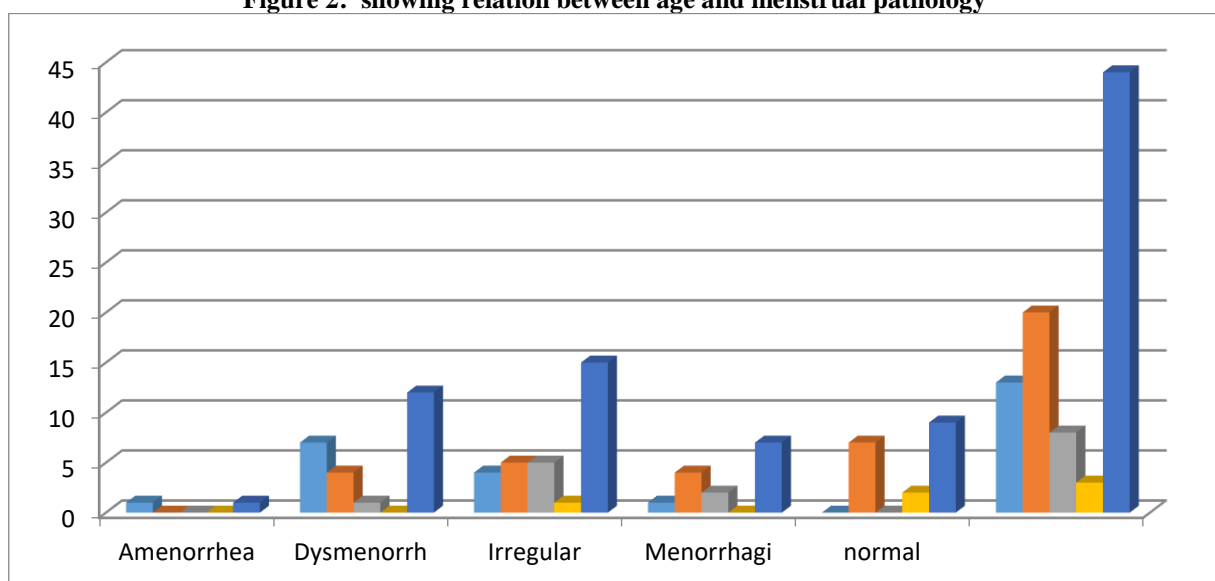
Table 2: Complaints of patients

History	Frequency	Percentage
Menstruation pathology	35	79.5
Infertility	9	20.5
Total	44	100.0

Above table shows history (complaints) in patients presented with infertility are menstrual pathology.

Table 3: Cross tabulation showing relation of age with menstrual pathology

Age	Amenorrhea	Dysmenorrhea	Irregular	Menorrhagia	Normal	Total
21-25	1	7	4	1	0	13
26-30	0	4	5	4	7	20
31-35	0	1	5	2	0	8
36-40	0	0	1	0	2	3
Total	1(2.3%)	12 (27.3%)	15 (34.1%)	7 (15.9%)	9(20.5%)	44

Figure 2: showing relation between age and menstrual pathology

In above table and figure shows menstruation related pathology, most common complaint is Irregular menstruation in 15 cases (34.1%) followed by dysmenorrhea in 12 cases(27.3%)

Table 4: Showing Type of Infertility

Infertility	Frequency	Percent (%)
Primary	33	75.0
Secondary	11	25.0
Total	44	100.0

Above table shows type of infertility primary and secondary, commonly presented cases are primary infertility.

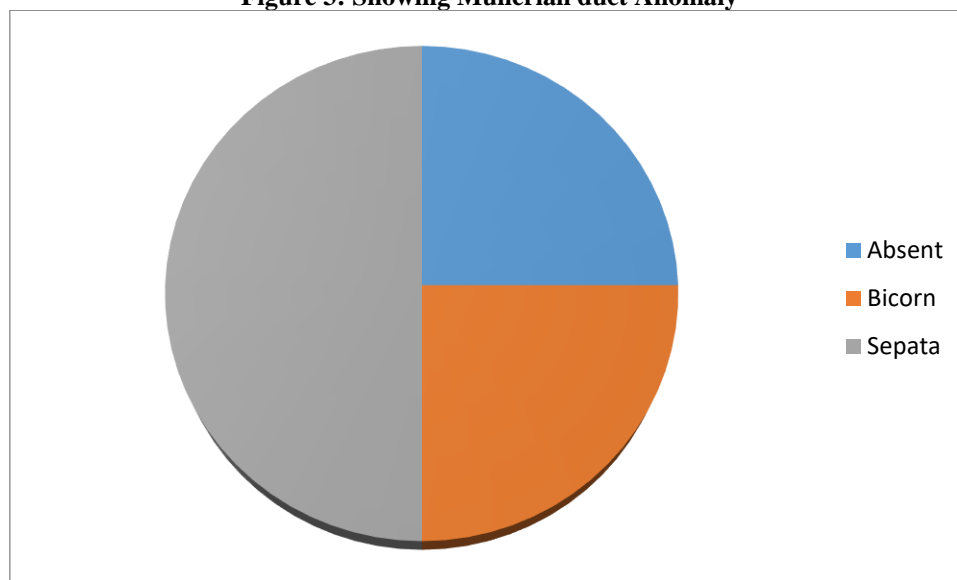
Table 5: Showing Pelvic pathology

Pelvic Pathology	Frequency	Percent (%)
Mullerian duct anomaly	4	9.1
Ovarian cause	18	40.9
PID	18	40.9
Uterine SOL	4	9.1
Total	44	100.0

Above table shows uterine anomalies in patients presented with infertility, which shows mullerian duct anomaly in 4 patients , PID and Ovarian pathology in 18 cases and space occupying lesions noted in 4 cases.

6: Showing Mullerian duct Anomaly

Anomaly	Frequency	Percent (%)
Absent uterus	1	2.3
Bicornuate Uterus	1	2.3
Sepatate, Subseptate uterus	2	4.5

Figure 3: Showing Mullerian duct Anomaly

Above table and figure diagram shows mullerian duct anomaly in infertility cases out of 4 case 2 cases shows septate/ Subseptate uterus followed by 1 & 1 cases of Absent uterus and bicornuate uterus.

Table 7: Showing Space occupying lesion (SOL) in uterus

SOL	Frequency	Percent (%)
Adenomyosis	1	2.3
Fibroid	3	6.8
No SOL	40	90.9
Total	44	100.0

Above table shows space occupying lesion in uterus which includes Fibroid in 3 cases and 1 with Adenomyosis.

Table 8: Showing ovarian pathology

Ovarian Pathology	Frequency	Percent (%)
PCOD	12	27.3
SOL	8	18.2
No pathology	24	54.5

Total	44	100.0
--------------	----	-------

Above table shows Ovarian causes in infertility, most common finding is PCOD in 12 cases (27.3%) followed by space occupying lesion(Focal lesion) 8 ovaries (18.2%).

Table 9: Showing both ovarian and uterine pathology

Pathology	Frequency	Percent
Yes	20	45.5
No	24	54.5
Total	44	100.0

Above table shows both ovarian and uterine pathology, in 20 (45.5%) cases common pathology seen.

DISCUSSION

Ultrasonography (USG) (mainly transvaginal/endovaginal) It is the first-line investigation and can be coupled with color Doppler and 3D/4D scans. It is readily available, inexpensive, noninvasive, radiation-free, relatively less time consuming, and easily repeatable. USG helps in determining the morphology of the uterus and ovaries, uterine and ovarian perfusion, and endometrial thickness, volume, and vascularity. It detects pathological lesions, including tubal lesions and abnormalities of follicular maturation and ovulation(4, 6). In our study 44 cases included in 6 month of duration of study who presented with menstrual irregularity, amenorrhea, dysmenorrhea, menorrhagia with infertility in the reproductive age group of 21-40 years. Most commonly cases seen in 26-30 years followed by 21-25 years of age group. Both primary and secondary infertility seen.

In study of Benksim A et al, A total of 619 infertile women were included in this study, 417 (67.37%) with primary infertility and 202 (32.63%) with secondary infertility (19) . In our study primary infertility seen in 33 (75.0%) cases and secondary infertility in 11 (25.0%) cases.

In study conducted by Benksim A et al, The average of women's ages were 28.7 ± 5.7 years and 31.95 ± 5.6 years in primary and secondary infertility, respectively. (19). In our study most common age group is 26-30 years followed by 21-25 years likely due to early marriage.

In the study conducted by Ramlau-Hansen CH et al, the rate of female infertility was significantly higher in secondary infertility than primary (66.10 vs. 44.20%). Also, the most common causes of female infertility were ovulation disorders, which manifest themselves by sparse or absent menstrual periods(20). In contrast to their study, our study shows primary infertility (75.0%) is more common than secondary infertility(25.0%).

A total of 86 patients with PID were examined by transvaginal sonography. At the time of admission, 31% of patients had a thick-walled ($>$ or $=$ 5 mm) echogenic tube raising the suspicion of pyosalpinx or pyo-ovary. During the following 3 months, 52% of patients developed tubes that were thin-walled ($<$ 5 mm) and poorly echogenic, and hydrosalpinx was suspected. At the first transvaginal sonographic examination, 64% showed no adnexal mass, but 16% of these developed suspected hydrosalpinx during the following 3 months. Of the total of 86 patients, 6% exhibited a hydrosalpinx for the first time after 3 months(21). In our study 18 (40.9%) patients shows PID which includes bulky uterus, endometrial collection, Nabothian cyst and adnexal mass.

Study conducted by Takahashi K et al, Among 104 patients, the mean age was 26 years, Maximum cases were seen in the age group of 26-30 years. Menstrual irregularities (91.3%) and infertility (51%) were the most common complaint(22).

In this study 15 to 20% of women in the reproductive age group have uterine fibroids(23). In our study fibroid seen in 3 (6.8%) cases and only one case is adenomyosis presented with secondary infertility.

CONCLUSION

Evaluation of infertility is impossible without ultrasound assessment. This tool helps all radiologist to examine the pelvic organs (ovaries, uterus, fallopian tube, peritoneal cavity) and is used to prediction of ovulation, endometrial receptivity and many disorders that may affect infertility. The diagnosis of infertility should be considered only after transvaginal scan and its correlation with biochemical parameters to rule out non ovarian and other non uterine causes..

REFERENCES:

- Gibbs RS, Karlan BY, Haney AF, Nygaard IE. Danforth's obstetrics and gynecology: Lippincott Williams & Wilkins Philadelphia; 2008.
- Okeke TC, Agwuna KK, Ezenyeaku CC, Ikeako LCJIJoR, Contraception, Obstetrics, Gynecology. Application of ultrasonography in female infertility: a comprehensive.4(5):1247.
- Sheethal C. Efficacy of TVS colour doppler in comparison of primary infertility with endometrial biopsy. 2016.
- Rastogi RJIJoR, Imaging. Role of imaging in female infertility [Dr. KM Rai memorial oration award]. 2010;20(03):168-73.
- Dechanet C, Brunet C, Anahory T, Reyftmann L, Hedon B, Dechaud HJJdGOeBdlR. Infertilit  du couple: de l'interrogatoire   l'orientation th rapeutique. 2009;38:F9-F18.
- Steinkeler JA, Woodfield CA, Lazarus E, Hillstrom MMJR. Female infertility: a systematic approach to radiologic imaging and diagnosis. 2009;29(5):1353-70.
- Ahmadi F, Akhbari F, Zamani M, Ramezanali F, Cheraghi RJAoIM. Value of endometrial echopattern at HCG administration day in predicting IVF outcome. 2017;20(2):0-.
- Rabinowitz R, Laufer N, Lewin A, Navot D, Bar I, Margalioth EJ, et al. The value of ultrasonographic endometrial measurement in the prediction of pregnancy following in vitro fertilization. 1986;45(6):824-8.

9. Raga F, Bonilla-Musoles F, Blanes J, Osborne NGJF, sterility. Congenital Müllerian anomalies: diagnostic accuracy of three-dimensional ultrasound. 1996;65(3):523-8.
10. Imaoka I, Kitagaki H, Sugimura KJN-DI. MR imaging associated with female infertility. 2000;45:440-50.
11. Yoder IJR. Diagnosis of uterine anomalies: relative accuracy of MR imaging, endovaginal sonography, and hysterosalpingography. 1992;185(2):343-.
12. Adams J, Polson D, Franks SJBMI. Prevalence of polycystic ovaries in women with anovulation and idiopathic hirsutism. 1986;293(6543):355-9.
13. Acar Şimşir MT, Yıldız MS. The potential role of uterine retroversion in pelvic pain symptoms and caesarean delivery. 2021.
14. Haq IU, Manzoor S, Rehman AU, Farooq AJAoKEMU. Role of ultrasonography in infertility management: Ovulation monitoring and assisted conception. 2010;16(4):257-.
15. Hackelöer B, Fleming R, Robinson H, Adam A, Coutts JJAJoO, gynecology. Correlation of ultrasonic and endocrinologic assessment of human follicular development. 1979;135(1):122-8.
16. Rokitansky KJZKGAW. Über Uterusdrusen-Neubildung in Uterus-unt Ovarialsarkomen. 1860;17:577.
17. Cullen TSJAoS. The distribution of adenomyomas containing uterine mucosa. 1920;1(2):215-83.
18. Kondagari L, Kahn J, Singh M. Sonography Gynecology Infertility Assessment, Protocols, And Interpretation. StatPearls [Internet]: StatPearls Publishing; 2022.
19. Benksim A, Elkhouidri N, Addi RA, Baali A, Cherkaoui MJJjof, sterility. Difference between primary and secondary infertility in Morocco: frequencies and associated factors. 2018;12(2):142.
20. Ramlau-Hansen CH, Thulstrup AM, Nohr E, Bonde JP, Sørensen T, Olsen JJHr. Subfecundity in overweight and obese couples. 2007;22(6):1634-7.
21. Taipale P, Tarjanne H, Ylöstalo PJUiO, Obstetrics GTOJotISoUi, Gynecology. Transvaginal sonography in suspected pelvic inflammatory disease. 1995;6(6):430-4.
22. Takahashi K, Eda Y, Abu-Musa A, Okada S, Yoshino K, Kitao MJHR. Endocrinology: Transvaginal ultrasound imaging, histopathology and endocrinopathy in patients with polycystic ovarian syndrome. 1994;9(7):1231-6.
23. SAKAMOTO R, IKATA T, MURASE M, HASEGAWA T, FUKUSHIMA T, HIZAWA KJS. Comparative study between magnetic resonance imaging and histopathologic findings in ossification or calcification of ligaments. 1991;16(11):1253-61.