

# Assessing awareness of varied uses of lasers in orthodontics

<sup>1</sup>Dr.M. Ketaki Kamath, <sup>2</sup>Dr. Karthikeyan M. K., <sup>3</sup>Dr. Vinoth Kumar R., <sup>4</sup>Dr. Vivekanandan

<sup>1</sup>Post Graduate Student, <sup>2</sup>Professor, Head of Department, <sup>3</sup>Reader, <sup>4</sup> Reader  
Department of Orthodontics and Dentofacial Orthopedics,  
Thai Moogambigai Dental College and Hospital, Chennai, India

## **INTRODUCTION**

Laser is the acronym for “Light Amplification by Stimulated Emission of Radiation” that dates back to approximately 50 years ago. In 1960, the first functioning laser was built by the American physicist Maiman at the Hughes Research Laboratories by using a synthetic ruby crystal made of aluminum oxide and chromium oxide.[1]

In general, lasers are composed of the three principal parts: An energy source, an active medium and a set of two or more mirrors that form a resonator. Properties such as wavelength are determined primarily by the active medium, which can be a gas, crystal or solid-state conductor. [2]

Laser light is produced as a result of the stimulation of the active medium with an external agent such as a flash lamp strobe device, an electrical current or an electrical coil. A laser beam has several physical characteristics that distinguish it from a typical white light source, including collimation, coherence [phase correlation] and monochromaticity [single wavelength]. [1]

For dental laser systems, the light is typically delivered to the target tissue through an optical fiber cable, a hollow waveguide or an articulated arm. [3]

Lasers used in dental practice vary between wavelengths of 488 nm and 10,600 nm. Dental lasers can be further classified in terms of the following characteristics: [4]

- Emission type: Spontaneous emission or stimulated emission
- Output power: High-powered, mid-powered or low-powered
- Active medium: Liquid, gas or solid state
- Target tissue: Hard or soft-tissue
- Potential biological damage: Class I, Class II, Class III or Class IV.

The primary lasers used in dentistry today are the argon, carbon dioxide [CO<sub>2</sub>], diode, neodymium-doped yttrium aluminum garnet [Nd: YAG] and the erbium lasers, erbium-doped yttrium aluminum garnet [Er: YAG] and erbium, chromium: yttrium-scandium-gallium-garnet [Er, Cr: YSGG], all of which are named for their active medium content and state of suspension. [4]

During a dental treatment, the effects of the laser on target tissues will depend on the wavelength, power output, exposure duration and the amount of energy delivered to the tissue.[5]

Most common dental procedures, including the removal of maxillary or lingual midline frenectomies, crown lengthening, composite curing, control of hemorrhage disorders, caries detection and removal, reduction of pain and treatments of hypersensitivity, gingivectomy, gingivoplasty, soft-tissue lesions and aphthous ulcers can all be effectively performed using dental lasers.[6]

Lasers cut by thermal ablation—decomposition of tissue through an instantaneous process of absorption, melting, and vaporization.[7] Essentially, the cells of the target tissue absorb the concentrated light energy, rapidly rise in temperature, and produce a micro-explosion known as spallation.[7] Thermal ablation depends on the amount of light energy absorbed.[8] The degree of absorption is determined by the wavelength [ $\lambda$ , measured in nanometers [nm]] of the laser, the electrical power of the surgical unit [measured in watts [W]], the time of exposure, and the composition of the tissues.[7,8,9]

## **DENTAL LASERS**

### **Argon Laser**

The argon laser, the active medium of which is argon gas, produces light at two wavelengths. The 488 nm blue light is commonly used to initiate the polymerization of restorative composite materials. The 514 nm blue-green light has maximum absorbance in tissues that are composed of pigmented molecules such as hemosiderin and melanin. Both wavelengths of the argon laser are poorly absorbed by non-pigmented and hard tissues. [3] This laser is often used for hemorrhage control in gingival surgery, as well as for detecting cracks and decay on the surface of teeth by using the transillumination technique. [7]

### **CO<sub>2</sub> Laser**

The active medium of this laser is CO<sub>2</sub> gas. It produces light at ~ 10,600 nm, which is invisible to the eye. This wavelength has a very high absorbance in water and the highest absorbance in hydroxyapatite as compared with other dental laser systems.[3] The CO<sub>2</sub> laser has some advantages, including rapid soft-tissue removal, perfect hemostasis and shallow depth of penetration, which is why it is commonly used for soft-tissue surgery. However, when using a CO<sub>2</sub> laser, the tooth structure surrounding the soft-tissue surgery site should be carefully protected. These lasers are not suitable for hard tissue applications. [5]

### **Erbium Lasers**

Today, erbium lasers are the most commonly used for dental applications. Types of erbium lasers used in dentistry include the Er:YAG and Er, Cr:YSGG.[2,7] The Er:YAG laser [2,940 nm] has YAG as its active medium, while the Er, Cr:YSGG [2,790 nm] has solid yttrium, scandium and garnet.[3] Both wavelengths exhibit high hydroxyapatite absorbance and the highest water absorbance of any dental laser. Because bone and tooth both contain great amounts of hydroxyapatite and water, erbium lasers can be successfully used in hard tissue removal. For such applications while the water in the tooth evaporates, the surrounding soft-tissues can be removed with a minimal thermal effect on the pulp.[10]

### **Nd:YAG Laser**

The first laser system designed for dentistry used a Nd:YAG, which has a crystal of YAG doped with neodymium as its active medium.[11] Its wavelength, 1,064 nm, has higher water and pigmented tissue absorption than the wavelength of CO<sub>2</sub> and Er: YAG lasers does. The Nd:YAG results in long-term hemostasis because of the thick coagulation layer. In addition to surgical applications, it has been used for soft-tissue removal [12] and researchers have also explored its use for non-surgical sulcular debridement. Because Nd: YAG light is only absorbed by dental hard tissue, it can safely be used to perform soft-tissue surgery adjacent to the teeth.

### **Diode Lasers**

Diode lasers use a semiconductor as the source for emission. Gallium aluminum arsenide [GaAlAs] and helium-neon [He-Ne] are two examples of semiconductor lasers. The active medium of the GaAlAs is solid, consisting of Ga, Ar and Al. Diode lasers used in dentistry vary between approximately 800 nm and 980 nm. Although light in this range is highly absorbed by pigmented tissues and has a great penetration depth in soft-tissues, it is poorly absorbed by dental hard tissues and water.[3] It is not as effective as the argon laser for hemostasis. Because light emitted from diode lasers is poorly absorbed by dental hard tissues, these lasers can be safely used for soft-tissue surgery applications, including gingival recontouring, crown lengthening, removal of hypertrophic tissue and frenectomies close to the enamel, dentine and cement. [2]

## **Materials and Methods**

### **Study Population**

A cross-sectional survey was conducted to obtain responses from dental practitioners around Chennai, Tamil Nadu, India, during the 2nd week of June 2020. A total of 300 responses were obtained.

### **Questionnaire**

The questionnaire consisting of 25 questions was designed using an online survey instrument [Google Forms] and was shared on various social media platforms. A self-structured questionnaire was formulated to assess the level of knowledge of orthodontic postgraduates in the varied use of lasers in orthodontics. The questions consisted of those that tested the knowledge and awareness of the uses of lasers, the safety precautions and their sterilization.

It was distributed online to orthodontic postgraduates to be filled and submitted. This research was carried out in the Department Of Orthodontics, Thai Moogambigai Dental College, Chennai.

### **Statistical Analysis**

Data was entered in Microsoft excel and later imported to SPSS IBM software tool [version 19, IBM Chicago] for statistical analysis.

### **Results**

Of the 300 dental practitioners, 174 [58%] were female and 126 [42%] were male. Their age ranged from 23 years to 53 years, with a mean of 32.4 [SD – 15] years.

#### **Regarding the awareness of different types of lasers employed in dentistry and orthodontics**

A significant number i.e. 95% [ $n = 285$ ] were aware of the different types of lasers employed. {Chart 1}

#### **Awareness that lasers can be used on dental soft and hard tissues**

To this, a good number 99% [ $n = 297$ ] of orthodontic PGs were aware of the varied uses. {Chart 1}

#### **Most important factors determining the tissue response to laser**

To this question, 47% [ $n = 141$ ] chose penetration depth and power output while 46% [ $n = 138$ ] chose the correct answer i.e. Laser wave length and energy density. {Chart 4}

#### **Awareness about Low Level Laser Therapy [LLLT]**

Majority of the respondents, 99% [ $n = 297$ ] had awareness about LLLT. {Chart 1}

#### **About how LLLT works**

To this, only 19% [ $n = 57$ ] chose the wrong answer of hemostasis. {Chart 5}

#### **LLLT causes RANKL increase in periodontal ligament and it can increase the rate of tooth movement during orthodontic treatment**

To this, 91% [ $n = 273$ ] were aware that LLLT causes RANKL and rate of orthodontic tooth movement increase. {Chart 2}

#### **Regarding effect of LLLT on bone regeneration**

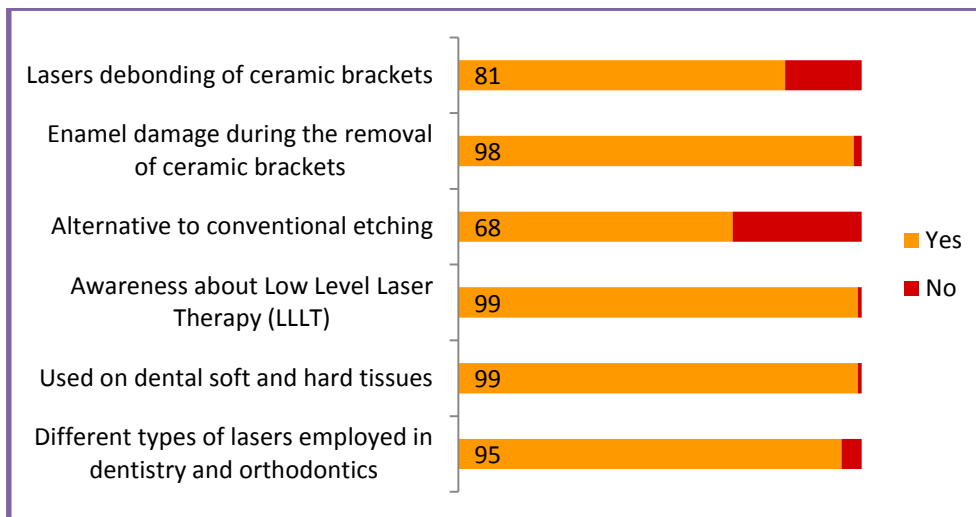
78% [ $n = 234$ ] were aware that LLLT accelerates bone regeneration. {Chart 6}

#### **About LLLT having positive effects on wound healing**

To this question, 89% [ $n = 267$ ] agreed to the correct statement. {Chart 2}

#### **Whether Laser etching is a viable alternative to conventional etching**

To this, 32% [ $n = 96$ ] disagreed with this statement. {Chart 1}



**Chart 1: Responses to questions with yes or no answers**

**Effect of Laser etching on enamel**

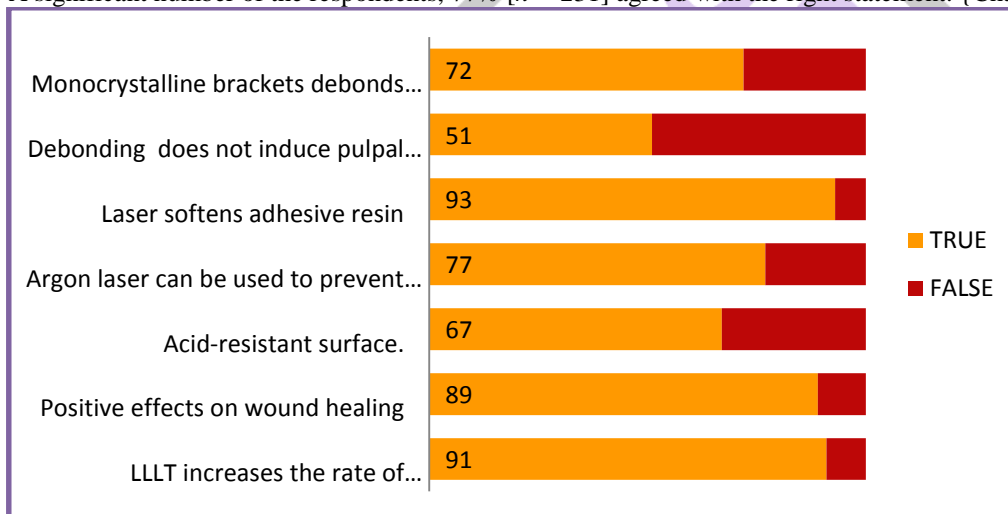
Regarding this, 39% [ $n = 117$ ] believed laser etching caused dissolution of enamel, while only 18% [ $n = 54$ ] and 50% [ $n = 150$ ] chose the right answer of melting and recrystallization. {Chart 7}

**Laser etching produces an acid-resistant surface**

To this, 67% [ $n = 201$ ] agreed with the right statement. {Chart 2}

**On whether Argon laser prevented enamel decalcification**

A significant number of the respondents, 77% [ $n = 231$ ] agreed with the right statement. {Chart 2}



**Chart 2: Questions regarding laser debonding, enamel decalcification, effects of laser on hard tissue.**

**Awareness that ceramic bracket debonding causes fractures and cracks in the enamel**

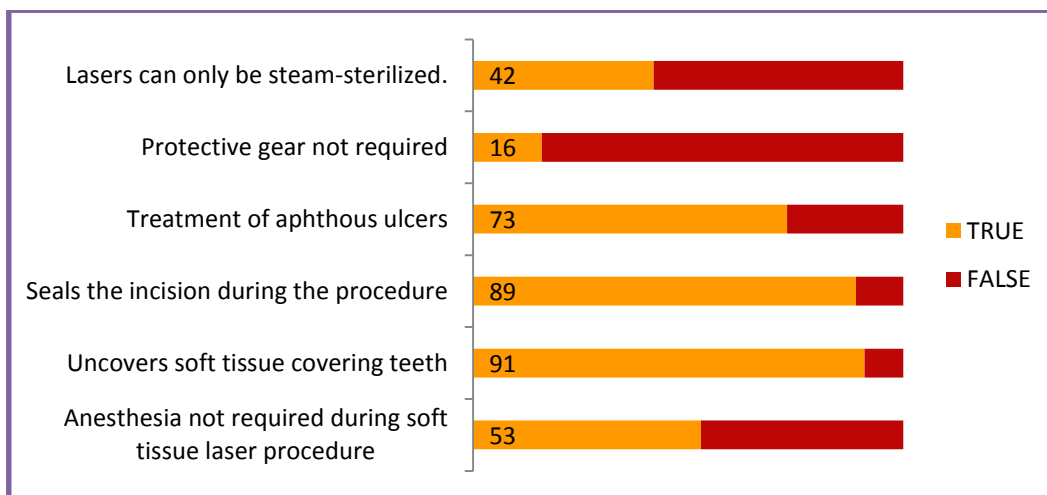
To this, 98% [ $n = 294$ ] of the respondents said they were aware of the statement. {Chart 1}

**Lasers can be used for debonding ceramic brackets**

To this, 81% [ $n = 243$ ] respondents agreed that lasers could be used for debonding. {Chart 1}

**Laser works by softening the adhesive resin allowing for easier debonding**

To this, 93% [ $n = 279$ ] agreed with the correct statement. {Chart 2}



**Chart 3: Questions regarding soft tissue uses of laser and laser safety.**

**Debonding with lasers does not induce pulpal damage**

To this, 51% [ $n = 153$ ] agreed with the false statement, as lasers have been found to induce slight pulpal damage. {Chart 2}

**On whether monocrystalline brackets require lower laser energy for debonding than polycrystalline brackets**

72% [ $n = 216$ ] agreed with the right statement. {Chart 2}

**Anesthesia is not required during a soft tissue laser procedure**

To this, 53% disagreed with the false statement. {Chart 3}

**Whether soft tissue laser can be used in the orthodontic office to uncover the crown of a partially erupted tooth and remove operculum of second molars**

To this, majority 91% [ $n = 273$ ] agreed that soft tissue laser can be used in the orthodontic office. {Chart 3}

**Laser seals the incision during the procedure; hence brackets and bands can be placed on the same day**

Regarding this, 89% [ $n = 267$ ] agreed with the correct statement. {Chart 3}

**Lasers can be used in the treatment of aphthous ulcers**

To this question, 27% [ $n = 81$ ] of the respondents were not aware that lasers can be used on aphthous ulcers. {Chart 3}


**Not necessary to wear protective gear during laser procedure**

To this, 84% [ $n = 252$ ] disagreed with the false statement. {Chart 3}

**Lasers can only be steam-sterilized**

Regarding this, 58% [ $n = 174$ ] disagreed with the right statement. {Chart 3}

**Q5. Factors determining the tissue response to laser**



**Chart 4: Responses for Q5.**

**Q7. Mode of action of LLLT**



**Chart 5: Responses for Q7.**

### Q9. Effect of LLLT on bone regeneration



Chart 6: Responses for Q9.

### Q12. Effect of laser etching on enamel



Chart 7: Responses for Q12.

#### Discussion

In orthodontic practice, lasers have numerous widespread purposes, including acceleration of tooth movement, bone remodeling, enamel etching prior to bonding, debonding of ceramic brackets and pain reduction after orthodontic force and inhibition of enamel demineralization. Soft-tissue applications such as frenectomies, gingival contouring and crown lengthening can also be accomplished using the dental lasers.

#### Reducing pain during orthodontic force application

It is well-known that following the appliance of orthodontic appliances, the patient feels pain or discomfort for 2-4 days. Low-level laser therapy [LLLT], during which the energy output is satisfactorily minimal to thwart a temperature rise above 36.5°C [normal body temperature] within the target tissue,[13] are often used as a fitting analgesic therapy for orthodontic patients.[14-21] this sort of therapy also has non-thermal and biostimulatory effects. Although the precise mechanism fundamental to the analgesic effect of LLLT isn't completely known, laser irradiation has neuropharmacological effects on the synthesis, release and metabolism of serotonin and acetylcholine within the central level, also as histamine and prostaglandin within the peripheral level. [22] Local CO<sub>2</sub> laser therapy has been found effective in reducing the pain related to orthodontic force applications. [23]

In this study, 60% [n = 180] were aware that LLLT reduced the extent of pain felt after the initial bonding appointment.

Tortamano et al. [19] concluded that LLLT effectively controls pain caused by the appliance of the primary archwire, but it doesn't affect the beginning of pain after the primary archwire is placed and doesn't alter the foremost painful day.

In conclusion, induction of laser analgesia may be a new treatment modality that has the benefits of being non-invasive, being easy to use and having no known adverse tissue reactions.

#### Effects On Tooth Movement

There are several studies concerned with the bio-stimulatory effects of LLLT. [22, 24] In 2004, Cruz et al. [25] investigated for the first time the consequences of LLLT on humans. For the 11 patients in the study, half the upper arch served as a control group, receiving mechanical activation of the canine teeth every 30 days. the other half received an equivalent mechanical activation, but was also irradiated with a diode laser. The results of the study showed significantly greater acceleration of canine retraction on the side treated with LLLT compared with the control.

In the current study, 80% of the respondents [n = 240] comprehended that LLLT increases the speed of orthodontic tooth movement. Similarly, Youssef et al. [20] investigated the consequences of LLLT on canine distalization rate. They irradiated with a Ga-Al-As diode laser [809 nm, 100 mW] on the 1st, 3rd, 7th and 14th days and reported that LLTH was effective at accelerating the tooth movement rate. Furthermore, Fujita et al. [26] concluded that LLLT stimulates tooth movement through induction of the receptor activator of the nuclear factor-kappa B [RANK] and RANKL. In their study, the amount of cells that showed positive immunoreactions to the primary antibodies of RANKL and RANK was significantly increased within the irradiation group on days 2 and 3 compared with the non-irradiation group.

Contrary to those studies, the study by Limpanichkul et al. [27] showed that Ga-Al-As [25 J/cm<sup>2</sup>] LLLT doesn't have any effect on the speed of orthodontic tooth movement. Although there has been no consensus on a correct application dose for exciting and



accelerating tooth movement, researchers advocate that LLLT for this purpose used laser energies varying from 2 to 54 J. [20, 24, 28-30]

### **Effects On Bone Regeneration**

A number of studies within the literature have shown that LLLT increases fibroblast proliferation and therefore the quantity of osteoid tissue. [31-33] Laser irradiation may play two principal roles in inducing bone formation.

The first is stimulation of cellular proliferation, especially nodule-forming cells of osteoblast lineage. The second is stimulation of cellular differentiation, especially to committed precursors, leading to a rise in the number of differentiated osteoblastic cells and an increase in bone formation.[33]

Saito and Shimizu reported that a GaAlAs diode laser [100 mW] can accelerate bone regeneration in a midpalatal suture during rapid palatal expansion. They advocate that LLLT inhibits relapse and reduces the retention period by accelerating bone regeneration within the midpalatal suture. [31]

Angeletti et al. evaluate the consequences of a GaAlAs laser [830 nm, 100 mW] on bone regeneration within the midpalatal anterior suture after surgically assisted rapid maxillary expansion in vivo. [30] consistent with their study, bone regeneration are often accelerated during the first stages of laser therapy. These results are important for orthodontic practice. However, it is important to recollect that the result of LLLT on bone regeneration after midpalatal suture expansion depends on total laser dose, the frequency of irradiation and therefore the application timing.

In vivo studies have shown that LLLT has positive effects on wound healing through acceleration of bone regeneration and stimulation of trabecular osteoid tissue formation and 78% of the respondents in this study acknowledged that LLLT accelerates bone regeneration and osteoid formation.

### **Enamel Etching During Bonding Procedures**

Physical changes like melting and recrystallization occur in enamel after laser irradiation, causing the formation of various pores and bubble-like inclusions. [34-36] This process is analogous to the sort III pattern produced by phosphoric acid. [37]

Due to this, laser irradiation may be a feasible method to etch enamel surfaces as an alternate to traditional acid etching.

Furthermore, laser etching of enamel and dentin are reported to generate a fractured, uneven surface and open dentin tubules, which is right for adhesion. [38]

Laser etching produces an acid-resistant surface. Laser radiation of dental hard tissues modifies the calcium-to-phosphorus ratio, reduces the carbonate-to-phosphate ratio, reduces water and organic component content and results in the formation of more stable, less acid-soluble compounds [thus reducing susceptibility to acid attack and caries]. [39]

Regarding this, majority of the study participants agreed that laser etching may be a viable alternative to acid etching which it produces an acid-resistant surface. However, a big percentage [39%] believed that laser etching caused dissolution of enamel, which is detrimental as compared to the melting and recrystallization that essentially occurs.

### **Enamel Decalcification Reduction**

Today, orthophosphoric acid etching appears to be the most effective method for preparing the enamel for the bonding of orthodontic attachments. After bonding, the enamel becomes more susceptible to carries thanks to increased plaque accumulation around the attachments. This often results in decalcification of the enamel or formation of white lesions and presents a serious problem for orthodontic patients. [40] it has been reported that the laser-irradiated enamel becomes acid resistant.[41] variety of studies showed that an argon laser can be used to prevent enamel decalcification by altering its crystalline structure.[40,42-44] Blankenau et al.[42] investigated the effectiveness of argon laser irradiation to scale back demineralization and loss of tooth structure in vivo. The experimental teeth during this study were irradiated with a 250 mW argon laser at ~ 12 J/cm<sup>2</sup> before banding and exhibited a 29% decrease in demineralization compared with the bilateral control teeth. Anderson et al. [40] also studied the in vivo effects of argon laser irradiation on enamel decalcification during treatment. In their study, nine volunteers underwent four first premolar extractions; these volunteers were then grouped by the following treatments: Non-pumiced, non-etched enamel; pumiced enamel and pumiced-etched enamel. The experimental groups received irradiation with an energy density of 100 J/cm<sup>2</sup> for 60 s. The authors concluded that argon laser irradiation is effective in reducing enamel decalcification during treatment and pumicing and etching before laser treatment doesn't reduce this effect. As it has been shown that laser etching makes enamel more resilient; it is achieved with argon lasers which 77% of the partakers in this study were aware of.

### **Ceramic Brackets Debonding**

Clinicians often encounter fractures and cracks within the enamel and brackets during the removal of ceramic brackets. With the appliance of laser irradiation, the adhesive resin are often softened, allowing light force to be applied during debonding. An Nd:YAG laser applying at 2 J or more is effective during the removal of monocryalline and polycryalline ceramic brackets, although it significantly decreases the bond strength to a greater extent for the polycryalline ceramic brackets than for monocryalline brackets. [45]

Feldon et al. [46] used a diode laser to irradiate monocryalline and polycryalline ceramic brackets for 3 s at 2 and 5 W/cm<sup>2</sup>, after they assessed shear bond strength and thermal effects on the pulp chamber. The authors observed that the laser treatment failed to decrease the debonding force required for the polycryalline ceramic brackets, but did significantly decrease the debonding force for the monocryalline brackets. The treatment did not increase the pulp chamber temperature. [46]

Strobl et al. [47] successfully debonded single crystal alumina [sapphire] and polycryalline alumina orthodontic brackets with both Nd: YAG [1,060 nm] and CO<sub>2</sub> [10.6 μm] lasers. They concluded that the debonding mechanism was thermal softening of the resin adhesive because of laser-induced heating of the labial surface of the bracket, wherein the heat was transmitted through the

bracket to the resin. [47]  
Majority of the participants were aware that enamel gets damaged during debonding which laser debonding of ceramic brackets aids by permitting lower debonding force application.

### **Effects On The Pulp**

When laser radiation is applied to a ceramic bracket, energy is absorbed and converted into heat. This heat is then free to propagate by conduction to the base of the bracket to soften the adhesive. [47] There is also the potential for this heat to propagate to the tooth structure and eventually cause pulp damage.

Ma et al [48] showed that debonding with 1.48 MPa of tensile load employing a CO<sub>2</sub> laser at 18 W for two seconds was successful in debonding 8 of 10 times and led to an intrapulpal temperature increase of 1.1°C [ $\pm$  0.81°C].

As previously described, debonding with a super-pulse CO<sub>2</sub> laser occurs at 2 W for fewer than 4 seconds [2.9 – 0.9]. As a result, the dental pulp showed a rise in temperature of 1.4°C. [49] This increase was below the temperature threshold required to cause pulpal damage. [50-54] a rise of 2.1°C of the dental pulp was evident at 3 W. However, there was no difference in shear bond strength when using 2 W instead of 3 W. Still, both temperatures were considered to be within the suitable physiological limit. [49] Obata et al concluded that there is no risk of pulp damage when a super pulse CO<sub>2</sub> laser is employed appropriately. [49] Ben-Baruch et al [55] and Ho et al [56] reported that the super CO<sub>2</sub> laser allowed for short laser pulses of microseconds, allowing a while for the tissue to cool down and decreasing damage to the pulp. Furthermore, super CO<sub>2</sub> lasers might induce vibration within the adhesion material, thus decreasing power output and minimizing the increase of temperature. [49] as compared, normal-pulse CO<sub>2</sub> lasers are more likely to cause thermal necrosis and charring due to continuous waves with millisecond-duration pulses. [49]

In this study, as much as 49% believed that laser debonding causes damage to pulp; when actually laser debonding using pulses of lasers allows sufficient time for cooling of the pulp thereby reducing the chance of pulpal damage.

### **Anesthesia In A Soft Tissue Laser Procedure**

Soft-tissue lasers equally coagulate and produce a mild anesthetic effect during excision; as such, topical anesthetic are often utilized in place of local infiltration. The topical anesthetic should be highly viscous, comprise several active anesthetic agents to supply a good spectrum of anesthetic action and contain a vaso-constrictive agent. [57] A topical mixture of lidocaine 20%, phenylephrine 2%, and tetracaine 4% is advocated. [ie, TAC 20% Alternate, Professional Arts Pharmacy, Baltimore, Md]. These topicals are contraindicated in elderly patients, patients with hypersensitivity to ester- and amide-type local anesthetics, para-aminobenzoic acid allergies, severe hypertension, hyperthyroidism, or cardiopathy. [58] So far, compound topical anesthetics, like TAC 20% Alternate, are neither FDA regulated nor unregulated drug products.

In the current study, 47% believed that laser procedures were painless and did not require anesthesia of any kind; whereas only topical anaesthesia is required rather than local infiltration.

### **Soft-Tissue Applications Related To Orthodontic Treatment**

Dental lasers deliver ease and precision during soft-tissue incision. They cause negligible tissue damage, bestow hemorrhage control and can also diminish post-operative pain. Soft-tissue applications related to orthodontic treatment include gingival re-contouring, exposure of un-erupted and partially erupted teeth, removal of hypertrophic and inflamed tissues, frenectomies, miscellaneous tissue and treatment of aphthous lesions.[59] Additionally, soft-tissue lasers are used for aesthetic contouring of the gingiva within the smile framework, establishing tooth proportionally prior to bracket placement, crown lengthening, treatment crown height asymmetry or contouring of gingival and interdental margins.[60]

Nd:YAG lasers are predominantly used for soft-tissue applications such as frenectomies, papillectomies and gingival incision.

### **Treatment Of Aphthous Ulcers**

One of the most uncomfortable experiences for orthodontic patients is the formation of aphthous ulcers. In the past, salt water rinses, various anesthetic and palliative mouth rinses and in particularly persistent and painful lesions, a prescription rinse of tetracycline and topical anesthetic have been prescribed. Some of these solutions help to differing degrees, but often they only make the situation bearable.

The diode laser offers a conceivable solution. The advocated technique involves using the laser on a very low-wattage setting, out of contact with the lesion [a distance of 1-2 mm], visualizing a spot large enough to cover the entire lesion. The laser is activated for 30 seconds, and in experience, the patient reports an immediate elimination of pain. The aphthous ulcer will generally heal and disappear approximately 1 day after laser treatment, compared with 10 to 14 days for an untreated lesion to heal. [61]

It has been shown that lasers help in the faster healing of aphthous ulcer; in accordance 73% of the participants in this study were aware of it.

### **Laser Safety And Harmful Effects Of Lasers**

According to the standards of American National Standards Institute and Occupational Safety and Health Administration, lasers are classified into four different classes based on potential danger, as follows: [62]

Class I: These are low-powered lasers that are safe to view

Class II a: These are low-powered visible lasers. They do not cause damage unless one looks directly along the beam for longer than 1,000 s

Class II: These are low-powered visible lasers. They are dangerous when viewed along the beam for longer than 0.25 s

Class III a: These are medium-powered lasers that are not dangerous when viewed for less than 0.25 s

Class III b: These are medium-powered lasers that are dangerous when viewed directly along the beam for any length of time

Class IV: These are dangerous high-powered lasers that can cause damage to the skin and eyes. Even the reflected or radiated beams are dangerous. It is necessary to take appropriate safety measures. Most of the lasers used for medical and dental purposes are in this category.

In addition, the inhalation of laser deposits consisting of organic materials, water vapor, carbon monoxide, carbon dioxide and hydrocarbon gas can be dangerous.

It is known that lasers operating at wavelengths below 400 nm [although not typically used in dentistry] have a detrimental effect to the skin. Lasers operating at non-visible wavelengths [ultraviolet and infrared] and reflection of laser light from various surfaces can also increase potential danger. Because the biggest risk is for the eyes, protective glasses must be worn by the patient and the practitioner during laser therapy. [63]

### **Eye Protection**

Awareness of the first type of eye protection can be traced back to 1962: with the development of the ruby laser, it was realized that lasers presented unique, specific hazards to the human eye. Lasers produce an intense, highly directional beam of light that is absorbed to some degree if directed, reflected, or focused on an object.

The eye is a critical target for laser injuries. The dentist, assistant, patient, and others who are inside the nominal hazard zone are at risk from the direct and reflected radiation of class III and class IV lasers [64].

Generally, protective glasses must have an optical density [OD] of at least 4 for the particular laser emission and device [65]. Eye protection manufacturers, however, must comply with the standards of the regulatory agencies when calculating the exact OD that provides the correct amount of attenuation for protection of the specific wavelength in question. Laser safety glasses must protect the eye structures from the specific wavelength in use, and the information about lens protection must be imprinted on the frames of the glasses or goggles [Fig. 2]. The actual color of the lenses themselves is not a reliable indicator of wavelength protection or OD requirement.

All glasses, however, must have side shields to protect the eyes from reflective laser energy. Regardless of the eye protection, a practitioner never should look directly at the laser beam. Activating the laser beam at times other than the test fire or toward the intended target tissue is unsafe and poses real direct or reflective beam hazards. [66]

Majority [84%] had awareness of the need for protective gear and eyewear during a laser procedure.

### **Sterilization And Infection Control**

Steam sterilization is the standard of care [17]. The small flexible optic fibers, hand-pieces, or tips must be steam sterilized in separate sterilization pouches after each use. They should be kept in the sterilization pouch until ready for use. It is essential that when using fiber-optically delivered lasers, the port [connecting] end remains clean and oil-free. Therefore, never run the fiber in a sterilizer cycle alongside a high-speed turbine with lubricant. If an instrument was used to cleave or re-cleave a fiber during or after a procedure, then it also must be steam sterilized.

The protective housing around the laser, including the control panel and articulating arm [if applicable] should receive the spray disinfectant/wipe/ spray disinfectant decontamination method, as do the dental cart and counter tops. Some delivery system components such as the large-diameter erbium fiber-optic cable are not designed for steam sterilization and must be disinfected in this way. [66]

In the current study, 58% were not aware of the fact that lasers can only be steam sterilized and this poses a risk of damage to the apparatus if the knowledge is implemented clinically.

### **Conclusion**

Almost 99% were aware of LLLT. About 81% knew lasers can be used for debonding. About 47% had knowledge that anesthesia is required during a soft tissue laser procedure. About 84% understood the importance of wearing protective gear during a laser procedure. As such, sufficient knowledge was there regarding the theory aspects of laser and its applications in orthodontics. Further studies need to be taken on the practical aspects to ascertain the level of clinical ease of application.

### **References**

- [1] Maiman TH. Stimulated optical radiation by ruby. *Nature* 1960;187:493-4.
- [2] Nalcaci R, Cokakoglu S. Lasers in orthodontics. *Eur J Dent* 2013;7:119-25.
- [3] Coluzzi DJ. Fundamentals of dental lasers: Science and instruments. *Dent Clin North Am* 2004;48:751-70.
- [4] Harris DM, Pick RM. Laser physics. In: Miserendino LJ, Pick RM, editors. *Lasers in Dentistry*. Singapore: Quintessence Publishing Co, Inc.; 1995. p. 27-38.
- [5] Lomke MA. Clinical applications of dental lasers. *Gen Dent* 2009;57:47-59.
- [6] Miserendino LJ, Pick RM. Current applications of lasers in dentistry. In: *Lasers in Dentistry*. Singapore: Quintessence Publishing Co, Inc.; 1995. p. 126-8.
- [7] Moritz A. Oral laser application. Chicago: Quintessence; 2006.
- [8] Rossman JA, Cobb CM. Lasers in periodontal therapy. *Periodontology* 2000 1995;9:150-64.
- [9] Sarver DM. Use of the 810 nm diode laser: soft tissue management and orthodontic applications of innovative technology. *Practice Proced Aesthet Dent* 2006;18: suppl 7-13.
- [10] van As G. Erbium lasers in dentistry. *Dent Clin North Am* 2004;48:1017-59, viii.
- [11] Goldstein A, White JM, Pick RM. Clinical applications of the Nd: YAG lasers. In: Miserendino LJ, Pick RM, editors. *Lasers in Dentistry*. Singapore: Quintessence Publishing Co. Inc.; 1995. p. 199-217.



- [12] Fornaini C, Rocca JP, Bertrand MF, Merigo E, Nammour S, Vescovi P. Nd: YAG and diode laser in the surgical management of soft tissues related to orthodontic treatment. *Photomed Laser Surg* 2007;25:381-92.
- [13] Harris DM. Biomolecular mechanism of laser biostimulation. *J Clin Laser Med Surg* 1991;8:277-80.
- [14] Harazaki M, Isshiki Y. Soft laser irradiation effects on pain reduction in orthodontic treatment. *Bull Tokyo Dent Coll* 1997;38:291-5.
- [15] Fukui T, Harazaki M, Muraki K, Sakamoto T, Isshiki Y, Yamaguchi H. The evaluation of laser irradiated pain reductive effect by occlusal force measurement. *Orthod Waves* 2002;61:199-206.
- [16] Lim HM, Lew KK, Tay DK. A clinical investigation of the efficacy of low level laser therapy in reducing orthodontic postadjustment pain. *Am J Orthod Dentofacial Orthop* 1995;108:614-22.
- [17] Saito S, Mikikawa Y, Usui M, Mikawa M, Yamasaki K, Inoue T. Clinical application of a pressure-sensitive occlusal sheet for tooth pain-time dependent pain associated with a multi-bracket system and the inhibition of pain by laser irradiation. *Orthod Waves* 2002;61:31-9.
- [18] Turhani D, Scheriau M, Kapral D, Benesch T, Jonke E, Bantleon HP. Pain relief by single low-level laser irradiation in orthodontic patient undergoing fixed appliance therapy. *Am J Orthod Dentofacial Orthop* 2006;130:371-7.
- [19] Tortamano A, Lenzi DC, Haddad AC, Bottino MC, Dominguez GC, Vigorito JW. Low-level laser therapy for pain caused by placement of the first orthodontic archwire: A randomized clinical trial. *Am J Orthod Dentofacial Orthop* 2009;136:662-7.
- [20] Youssef M, Ashkar S, Hamade E, Gutknecht N, Lampert F, Mir M. The effect of low-level laser therapy during orthodontic movement: A preliminary study. *Lasers Med Sci* 2008;23:27-33.
- [21] Xiaoting L, Yin T, Yangxi C. Interventions for pain during fixed orthodontic appliance therapy. A systematic review. *Angle Orthod* 2010;80:925-32.
- [22] De Nguyen T, Turcotte JY. Lasers in dentistry and in oral and maxillofacial surgery. *J Can Dent Assoc* 1994;60:227-8, 231.
- [23] Fujiyama K, Deguchi T, Murakami T, Fujii A, Kushima K, Takano-Yamamoto T. Clinical effect of CO [2] laser in reducing pain in orthodontics. *Angle Orthod* 2008;78:299-303.
- [24] Sun G, Tunér J. Low-level laser therapy in dentistry. *Dent Clin North Am* 2004;48:1061-76.
- [25] Cruz DR, Kohara EK, Ribeiro MS, Wetter NU. Effects of low-intensity laser therapy on the orthodontic movement velocity of human teeth: A preliminary study. *Lasers Surg Med* 2004;35:117-20.
- [26] Fujita S, Yamaguchi M, Utsunomiya T, Yamamoto H, Kasai K. Low-energy laser stimulates tooth movement velocity via expression of RANK and RANKL. *Orthod Craniofac Res* 2008;11:143-55.
- [27] Limpanichkul W, Godfrey K, Srisuk N, Rattanayatikul C. Effects of low-level laser therapy on the rate of orthodontic tooth movement. *Orthod Craniofac Res* 2006;9:38-43.
- [28] Kawasaki K, Shimizu N. Effects of low-energy laser irradiation on bone remodeling during experimental tooth movement in rats. *Lasers Surg Med* 2000;26:282-91.
- [29] Altan BA, Sokucu O, Ozkut MM, Inan S. Metrical and histological investigation of the effects of low-level laser therapy on orthodontic tooth movement. *Lasers Med Sci* 2012;27:131-40.
- [30] Goulart CS, Nouer PR, Mouramartins L, Garbin IU, de Fátima Zanirato Lizarelli R. Photoradiation and orthodontic movement: Experimental study with canines. *Photomed Laser Surg* 2006;24:192-6.
- [31] Saito S, Shimizu N. Stimulatory effects of low-power laser irradiation on bone regeneration in midpalatal suture during expansion in the rat. *Am J Orthod Dentofacial Orthop* 1997;111:525-32.
- [32] Angeletti P, Pereira MD, Gomes HC, Hino CT, Ferreira LM. Effect of low-level laser therapy [GaAlAs] on bone regeneration in midpalatal anterior suture after surgically assisted rapid maxillary expansion. *Oral Surg Oral Med Oral Pathol Oral Radiol Endod* 2010;109:e38-46.
- [33] Ozawa Y, Shimizu N, Kariya G, Abiko Y. Low-energy laser irradiation stimulates bone nodule formation at early stages of cell culture in rat calvarial cells. *Bone* 1998;22:347-54.
- [34] Zakariasen KL, MacDonald R, Boran T. Spotlight on lasers. A look at potential benefits. *J Am Dent Assoc* 1991;122:58-62.
- [35] Walsh LJ, Aboud D, Brockhurst PJ. Bonding of resin composite to carbon dioxide laser-modified human enamel. *Dent Mater* 1994;10:162-6.
- [36] Nelson DG, Wefel JS, Jongebloed WL, Featherstone JD. Morphology, histology and crystallography of human dental enamel treated with pulsed low-energy infrared laser radiation. *Caries Res* 1987;21:411-26.
- [37] Silverstone LM, Saxton CA, Dogon IL, Fejerskov O. Variation in the pattern of acid etching of human dental enamel examined by scanning electron microscopy. *Caries Res* 1975;9:373-87.
- [38] Visuri SR, Gilbert JL, Wright DD, Wigdor HA, Walsh JT Jr. Shear strength of composite bonded to Er: YAG laser-prepared dentin. *J Dent Res* 1996;75:599-605.
- [39] Lee BS, Hsieh TT, Lee YL, Lan WH, Hsu YJ, Wen PH, et al. Bond strengths of orthodontic bracket after acid-etched, Er: YAG laser-irradiated and combined treatment on enamel surface. *Angle Orthod* 2003;73:565-70.
- [40] Anderson AM, Kao E, Gladwin M, Benli O, Ngan P. The effects of argon laser irradiation on enamel decalcification: An in vivo study. *Am J Orthod Dentofacial Orthop* 2002;122:251-9.
- [41] Sognnaes RF, Stern RH. Dental laboratories accredited for 1965 by southern california state dental association. *J South Calif Dent Assoc* 1965; 33:396-403.
- [42] Blankenau RJ, Powell G, Ellis RW, Westerman GH. In vivo caries-like lesion prevention with argon laser: Pilot study. *J Clin Laser Med Surg* 1999; 17:241-3.

- [43] Oho T, Morioka T. A possible mechanism of acquired acid resistance of human dental enamel by laser irradiation. *Caries Res* 1990; 24:86-92.
- [44] Noel L, Rebellato J, Sheats RD. The effect of argon laser irradiation on demineralization resistance of human enamel adjacent to orthodontic brackets: An in vitro study. *Angle Orthod* 2003; 73:249-58.
- [45] Hayakawa K. Nd: YAG laser for debonding ceramic orthodontic brackets. *Am J Orthod Dentofacial Orthop* 2005; 128:638-47.
- [46] Feldon PJ, Murray PE, Burch JG, Meister M, Freedman MA. Diode laser debonding of ceramic brackets. *Am J Orthod Dentofacial Orthop* 2010; 138:458-62.
- [47] Strobl K, Bahns TL, Willham L, Bishara SE, Stwalley WC. Laser-aided debonding of orthodontic ceramic brackets. *Am J Orthod Dentofacial Orthop* 1992;101:152-8.
- [48] Ma T, Marangoni RD, Flint W. In vitro comparison of debonding force and intrapulpal temperature changes during ceramic orthodontic bracket removal using carbon dioxide laser. *Am J Orthod Dentofacial Orthop* 1997;111:203-10.
- [49] Obata A, Tsumura T, Niwa K, Ashizawa Y, Deguchi T, Ito M. Super pulse CO2 laser for bracket bonding and debonding. *Eur J Orthod* 1999;21:193-8.
- [50] Zach L, Cohen G. Pulp response to externally applied heat. *Oral Surg Oral Med Oral Path* 1965;19:515-30.
- [51] Pohto M, Sheinin A. Microscopic observations on living dental pulp, Part 2. *Acta Odontol Scand* 1957;24:303-14.
- [52] Serebro L, Segal T, Nordenberg D, Gorfil C, Bar-Lev M. Examination of tooth pulp following laser beam irradiation. *Lasers Surg Med* 1987;7:236-9.
- [53] Goodis HE, Schein B, Stauffer P. Temperature changes measured in vivo at the dentinoenamel junction and pulpodentin junction during cavity preparation in the Macaca fascicularis monkey. *J Endod* 1988;14:336-9.
- [54] Rickoff B, Trowbridge H, Baker J, Fuss Z, Bender IB. Effects of thermal vitality test on human dental pulp. *J Endod* 1988;14: 482-5.
- [55] Ben-Baruch G, Fidler JP, Wessler T, Bendick P, Schellhas F. Comparison of wound healing between chopped mode-super pulse mode CO2 laser and steel knife incision. *Lasers Surg Med* 1988;8:596-9.
- [56] Ho C, Nguyen Q, Lowe NJ, Griffin ME, Lask G. Laser resurfacing in pigmented skin. *Dermatol Surg* 1995;21:1035-7.
- [57] Graham JW. Profound, needle-free anesthesia in orthodontics. *J Clin Orthod* 2006;40:723-4.
- [58] Kravitz ND, Kusnoto B. Placement of mini-implants with topical anesthetic. *J Clin Orthod* 2006;40:602-4.
- [59] Sarver DM, Yanosky M. Principles of cosmetic dentistry in orthodontics: Part 3. Laser treatments for tooth eruption and soft tissue problems. *Am J Orthod Dentofacial Orthop* 2005;127:262-4.
- [60] Sarver DM, Yanosky M. Principles of cosmetic dentistry in orthodontics: Part 2. Soft tissue laser technology and cosmetic gingival contouring. *Am J Orthod Dentofacial Orthop* 2005;127:85-90.
- [61] Sarver DM, Yanosky M. Principles of cosmetic dentistry in orthodontics: part 3. Laser treatment for tooth eruption and soft tissue problems. *Am J Orthod Dentofacial Orthop* 2005;127:85-90.
- [62] Miserendino LJ, Pick RM, Blankenau RJ. Laser safety in dental practice. In: Miserendino LJ, Pick RM, editors. *Lasers in Dentistry*. Singapore: Quintessence Publishing Co, Inc.; 1995. p. 85-103.
- [63] Nalcaci R, Cokakoglu S. Lasers in orthodontics. *Eur J Dent* 2013;7:119-25.
- [64] Sliney DH. Laser safety. *Lasers Surg Med* 1995;16[3]:215-25.
- [65] Sliney DH, editor. Guide for the selection of laser eye protection. 3rd edition. Orlando [FL]: Laser Institute of America; 1995.
- [66] Piccione PJ. Dental laser safety. *Dent Clin North Am*. 2004;48[4]:795-v.