

# SINGLE VISIT ENDODONTIC THERAPY: A REVIEW

DR. SHAKIR HUSSAIN RATHER<sup>1</sup>, DR. SANGITA SINGH<sup>2</sup>, DR. NISHMA NIHARIKA<sup>3</sup>, DR. SONAM SAH<sup>4</sup>,  
DR. SAMUEL SANTHA KUMAR<sup>5</sup>

<sup>1</sup>Private Practitioner, Dr. Shakir's Dentzmania Dental Care, Shopian, Jammu and Kashmir, India

<sup>2,3,4</sup>PG Student, Kalka Dental College and Hospital, Meerut, India

<sup>5</sup>Private Practitioner, Sam's Dental Care, Arakkonam, Tamil Nadu, India

**Abstract:** The concept of single visit root canal treatment is predicted on the entombing theory which states that the large number of microorganisms are removed during cleaning and shaping and therefore the remaining bacteria are entombed by the root canal obturation and it will miss the essential elements to survive. The main objective of performing root canal therapy is to eliminate bacteria from the infected root canal system or remove inflamed pulp tissue and close it with a biologically acceptable filling material. The recent advances in Endodontic technology attracts the dental practitioners to perform the root canal treatment in single visit. Studies concerning postoperative pain as well as healing rates shows the treatment outcome to be similar whether completed in single or multiple visits. In single sitting root canal treatment it offers many advantages like decreases the number of operative procedure, additional anesthesia, gingival trauma and eliminating the risk of inter appointment leakage through temporary restoration.

**Keywords:** Single and Multiple visit root canal treatment, post-operative complications and Periapical healing.

## INTRODUCTION

A successful endodontic treatment depends upon localization, proper chemo mechanical preparation of the root canal system, debridement, shaping, disinfection, and three-dimensional obturation of canal system. To achieve this, endodontic therapy used to be performed in multiple visits for complete disinfection of the canals<sup>1</sup>. Single-visit endodontics<sup>2</sup> is defined as "the conservative non-surgical treatment of an endodontically involved tooth consisting of complete biomechanical cleansing, shaping, and obturation of the root canal system during one visit". In the era of modern endodontics, it is important to view single visit endodontics as a supplemental procedure that compliments total patient care. The concept of single visit root canal treatment is based on the entombing theory, which the large number of microorganisms removed during cleaning and shaping and the remaining bacteria entombed by the root canal obturation, therefore it will miss the essential elements to be survive nutrition and space. In addition, the antimicrobial activity of the sealer or the zinc (Zn) ions of gutta-percha can kill the residual bacteria<sup>3</sup>. Studies concerning postoperative pain as well as healing rates shows the treatment outcome to be similar whether completed in one or multiple visits<sup>4</sup>. In addition to this, treatment in one visit offers many advantages. This decreases the number of operative procedure including additional anesthesia, gingival trauma from rubber dam application as well as eliminating the risk of inter appointment leakage through temporary restoration and less time consuming resulting in less cost to the patients<sup>5,6</sup>. Proponents of multiple visit procedures contend that antimicrobial property of inter appointment calcium hydroxide<sup>7,8</sup> placement is required to ensure successful healing, although predictable levels of bacterial reduction via refined cleaning and shaping techniques is one appointment may negate this need<sup>9</sup>. The clinician should wisely choose the technique that best fits patient's circumstances. In the last few years it has evolved from just an empirical technique to an acceptable treatment procedure for specific endodontic problems and the recent advances, helps the dental practitioners and endodontists to perform the root canal treatment in single visit.

**SINGLE VISIT ROOT CANAL TREATMENT:** Single visit treatment is an approach where in access opening, cleaning and shaping with irrigation and obturation is done in a single sitting.

## SELECTION CRITERIA FOR SINGLE VISIT ENDODONTICS:

**OLIET'S CRITERIA FOR CASE SELECTION**<sup>10,11</sup> Patient should be cooperative and prepared for single visit endodontics and non-cooperative patients with TMJ problems, limited mouth opening should be avoided for single visit endodontics:

1. Positive patient acceptance.
2. Sufficient time to complete procedure
3. Absence of acute symptoms requiring drainage through the canal and of persistent continuous flow of exudate or blood.
4. Absence of anatomic obstacles like calcification in the canals and procedural difficulties (ledge formation, blockage, perforation, inadequate fills).

Ideal endodontic therapy would eliminate all pain that exists in the involved tooth. But, the physiodynamics of the inflammatory process do not allow pain to immediately disappear once the source of the pain is eradicated. Asymptomatic nonvital pulp is the most controversial situation for one visit endodontics<sup>12</sup>. Clinical research on this subject have concluded that there is no greater incidence in postoperative pain when comparing single with multivisit procedures performed on teeth containing non vital pulps with and without the presence of associated periapical radiolucency. Also, teeth with nonvital pulps associated with sinus tract appear is least likely to cause post-operative discomfort<sup>13,14</sup>. Postoperative pain after non-surgical root canal treatment has been reported to range from 3 to 50%<sup>15,16,17</sup>. Ferrangi P<sup>18</sup> reported relatively low incidence of pain following single visit procedure. O'Keefe<sup>19</sup> found no significant difference in postoperative pain experience by his patient following single visit or multiple visit root canal treatment. Roane et al<sup>20</sup> reported 2:1 higher frequency of pain following treatment completed in multiple visit as compared to that reported for those treated with single visit. Mulhern et al.<sup>5,14</sup> concluded that there was no significant difference in the incidence

of postoperative pain between one-visit and multiple-visit endodontic treatment of asymptomatic pulpal necrosis. Moreover, pain associated with root canal therapy is poor indicator of pathosis and even more unreliable predictor of long term success<sup>21,22</sup>.

### INDICATIONS

- Uncomplicated vital teeth
- Physically compromised patient
- Medically compromised patients
- Fractured anterior where esthetics is a concern
- Apprehensive but cooperative patient
- Sedation
- Uncomplicated non vital teeth with sinus tract

### CONTRAINDICATIONS

- ✓ Teeth with anatomic anomalies for e.g. calcified and curved canals
- ✓ Patients with allergies or previous flare ups
- ✓ Acute alveolar abscess cases with presence of pus discharge
- ✓ Patients who cannot keep mouth open for long duration (TMJ disorders)
- ✓ Symptomatic non vital teeth and presence of no sinus tract
- ✓ Asymptomatic non vital teeth with presence of periapical pathology
- ✓ Patients who have acute apical periodontitis with severe pain on percussion
- ✓ Teeth with limited access

### ADVANTAGES

- Patient comfort
- Minimizes fear and anxiety
- Familiarity of the canal anatomy
- Reduced intra appointment pain

### DISADVANTAGES

- ❖ Flare ups
- ❖ Hemorrhage
- ❖ Extremely fine, calcified, multiple canals cause stress for both the patient and the clinician
- ❖ Inexperienced clinicians

### RECENT ADVANCES THAT ASSISTANT IN PERFORMING SINGLE VISIT ENDODONTIC THERAPY

- Use of direct digital radiography.
- Use of surgical microscope.
- Use of apex locators.
- Crown down technique is preferred because of less chance of pushing debris and bacteria into the periapical area and also for easier preparation of the apical portion of the canal.
- NiTi rotary instrumentation and ultrasonic will aid in rapid canal preparation.
- Use of NaOCl and H<sub>2</sub>O<sub>2</sub> irrigants help in faster removal of debris.
- Newer thermo-plasticized injectable guttapercha can assist in rapid obturation.

### STEPS IN SINGLE VISIT TREATMENT<sup>23</sup>

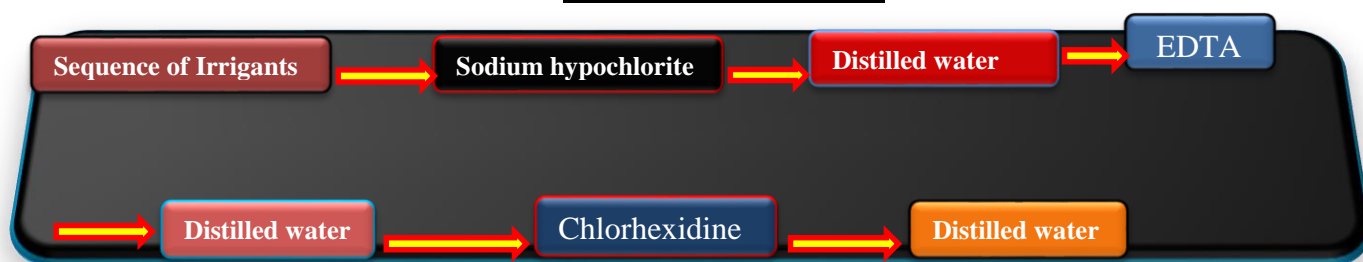
#### 1. ACCESS OPENING, CLEANING AND SHAPING:

Access opening done using a round and tapered fissure bur till a “drop” is felt indicating that the pulp chamber is entered. Cleaning and shaping is done using finger files or rotary files with intermittent irrigation.

#### 2. IRRIGATION TECHNIQUE FOR SINGLE VISIT TREATMENT:

Irrigation is done frequently to remove and loosen debris and microorganisms and to ensure that the debris are not pushed out the apex. Thus, this helps in flushing, lubrication, and smear layer removal. The most commonly used irrigants include:

1. EDTA (Ethylene diaminetetraacetic acid) (17%)
2. Chlorhexidine 0.2%
3. Sodium hypochlorite 5.25%
4. Citric acid 50%
5. Distilled water

**IRRIGATION SEQUENCE<sup>23</sup>****CONCLUSION**

The case selection should be done properly and all the indications and contraindications in each case on an individual basis that a decision should be made as to whether or not it can be completed in a single visit. Briefly, in cases of vital pulp, a single-visit treatment should be used whenever possible. This is based on the fact that the pulp is only superficially infected and the root canal is free of bacteria. Therefore, there is no apparent reason not to treat vital pulps in a single visit. If the pulp is necrotic or associated with a periradicular disease, there is ample evidence that the root canal system is infected. In these cases, the root canal system should ideally be cleaned and shaped, an intracanal medication placed, and the canal filled at a second appointment. Both single and multivisit treatments should be viewed as part of a total endodontic treatment spectrum, with the choice of one over the other being determined by the circumstances surrounding each individual case. However, when doubt exists, the multiple visit procedure should be performed. Thus, the clinician will be most effectively utilizing his time in delivering the best possible endodontic service available to the patient.

**REFERENCES**

- [1] Ahmed F, Thosar N, Baliga MS, Rath N. single visit endodontic therapy: A review. *Austin J Dent*. 2016;3(2):1035.
- [2] Ashkenaz PJ. One-visit endodontics. *Dent Clin North AM* 1984;28:853-63.
- [3] Al-Rahabi M, Abdulkhayum AM. Single visit root canal treatment: Review. *Saudi Endod J* 2012;2:80-4.
- [4] Soltanoff W. A comparative study of the single-visit and the multiple visit endodontic procedure. *J Endod*. 1978;4(9):278-81.
- [5] Figini L, Lodi G, Gorni F, Gagliani M. Single versus multiple visits for endodontic treatment of permanent teeth: A Cochrane review. *J Endod* 2008;34:1041-47.
- [6] El Mubarak AH, Abu-bakr NH, Ibrahim YE. Postoperative pain in multiple-visit and single-visit root canal treatment. *J Endod* 2010 Jan;36:36-9.
- [7] Weiger R, Rosendahl R, Lost C. Influence of calcium hydroxide intracanal dressings on the prognosis of teeth with endodontically induced periapical lesions. *Int Endod J*. 2000;33(3):219-45.
- [8] Ghoddusi J, Javidi M, Zarrabi MH, Bagheri H. Flare-ups incidence and severity after using calcium hydroxide as intracanal dressing. *N Y State Dent J* 2006;72:24-8.
- [9] Peters LB, Wesselink PR. Periapical healing of endodontically treated teeth in one and two visits obturated in the presence or absence of detectable microorganisms. *Int Endod J* 2002;35:660-7.
- [10] Oliet S. Single-visit Endodontics: A Clinical Study. *J Endod*. 1983;9(4):1-6.
- [11] Oliet S. Single-visit endodontics: A clinical study. *J Endod* 1983;9:147-52.
- [12] Nivethithan T, Raj JD. Endodontic pain-cause and management: a review. *Int J Pharm Sci Res*;6(7):2723-7.
- [13] Oginni A, Udoeye CI. Endodontic flare-ups: comparison of incidence between single and multiple visits procedures in patients attending a Nigerian teaching hospital. *Odontostomatol Trop* 2004;27:23-7.
- [14] A Gustavo, M Eduardo, S Alexandre, Bueno C, Nowakowski A, Cunha R. Influence of Irrigating Solution on Postoperative Pain Following Single-Visit Endodontic Treatment: Randomized Clinical Trial. *J Can Dent Assoc* 2010;76-82.
- [15] Mulhern JM, Patterson SS, Newton CW, Ringel AM. Incidence of postoperative pain after one appointment endodontic treatment of asymptomatic pulpal necrosis in single-rooted teeth. *J Endod* 1982 Aug;8(8):370-375.
- [16] Walton R, Fouad A. Endodontic interappointment flare-ups: a prospective study of incidence and related factors. *J Endod* 1992 Apr;18(4):172-177.
- [17] Torabinejad M, Cymerman JJ, Frankson M, Lemon RR, Maggio JD, Schilder H. Effectiveness of various medications on postoperative pain following complete instrumentation. *J Endod* 1994 Jul;20(7):345-354.
- [18] Ferrangi P. Treatment of root canals of infected teeth in one appointment: a report of 340 cases. *Dent Dig* 1959;65:490-494.
- [19] O'Keefe EM. Pain in endodontic therapy: preliminary study. *J Endod* 1976 Oct;2(10):315-319.
- [20] Roane JB, Dryden JA, Grimes EW. Incidence of postoperative pain after single and multiple-visit endodontic procedures. *Oral Surg Oral Med Oral Pathol* 1983 Jan;55(1):68-72.
- [21] Taintor JF, Langeland K, Valle GF, Krasny RM. Pain: a poor parameter of evaluation in dentistry. *Oral Surg Oral Med Oral Pathol* 1981 Sep;52(3):299-303.
- [22] Wang C, Xu P, Ren L, Dong G, Ye L. Comparison of post-obturation pain experience following one-visit and two-visit root canal treatment on teeth with vital pulps: a randomized controlled trial. *Int Endod J* 2010 Aug;43:692-7.
- [23] 1-2-3 steps in endodontic irrigation By Philippe Sleiman, DDS, DUA, MSc, PhD, FICD: Endo tribune US edition 2008