

Comparative study of single and two stage repair of hypospadias

¹Dr. Koli Nikhil Vanura, ²Dr. Satyanarayan V, ³Dr. Shivkumar Babu M.G

¹Senior Resident, General Surgery, ESIC Medical College, Kalaburagi, India

²Professor, General Surgery, ESIC Medical College & PGIMSR, Rajajinagar, Bengaluru, India.

³Professor and Head, Department of Urology, ESIC Medical College & PGIMSR, Rajajinagar, Bengaluru, India.

Abstract -

Introduction: Hypospadias is a common congenital malformation, occurring in about 1 in 300 live births, with proximal hypospadias being identified in 20% of cases. Compared with distal hypospadias, the proximal type usually has a higher incidence of complications. Some surgeons prefer single-stage urethroplasty (e.g. TIP urethroplasty and modified Koyanagi technique), whereas others advocate two-stage repair to achieve better functional and cosmetic outcomes urethroplasty. Hence, objectives of our study are comparing single and two stage repair of hypospadias with respect to post operative complications, surgical outcome and post-operative follow up.

Methods: A total of 50 hypospadias patients were enrolled in the study. Demographic, clinical profile, biochemical and laboratory tests parameter were obtained. Patients were divided into two groups 25 in each group, one undergoing one stage repair- TIP urethroplasty and the other two stage (Bracka's) repair groups using computer generated randomization. Patients were assessed for post-operative complications, surgical outcome using HOSE score and post-operative follow up. Data was analysed using SPSS.

Results: Post-operative complications were insignificant between the two groups in Distal and Mid Shaft Hypospadias, but in Proximal Hypospadias, one stage repair had significantly higher complications when compared to two stage repair. Surgical Outcome assessed by HOSE score had acceptable outcome in One stage repair for Distal and Midshaft Hypospadias with Restriction in Proximal Hypospadias, whereas in two stage repair group, all types of Hypospadias had an acceptable outcome. Mean postoperative follow up was less in one stage repair in comparison with two stage repair.

Interpretation & Conclusion: One Stage Repair appears to be a good choice due to its lower complication rate with good cosmetic results and shorter follow up in distal and mid shaft hypospadias. The staged repair is a safe and reliable approach in patients with all types of hypospadias. The procedure can be accomplished with a low-complication rate and with a good final cosmetic result in proximal hypospadias compared to one stage repair.

Keywords: Hypospadias; TIP urethroplasty; Bracka's two stage repair.

INTRODUCTION

Hypospadias repair is one of the commonest operations done in pediatric surgery centers, with an incidence of 1 in 200 to 1 in 300^[1]. The term hypospadias stems from two Greek words: hypo, which means 'below' and spadon, which means 'hole'. The anomaly is characterized by a urethral meatus ectopically located proximal to the normal place on the ventral side of the penis. Different anatomic presentations can be observed. The position of the urethral meatus can be classified as anterior or distal (glandular, coronal, or subcoronal; 60–65% of cases), middle (midpenile; 20–30% of cases), or posterior or proximal (posterior penile, penoscrotal, scrotal, or perineal; 10–15% of cases)^[2].

Surgical techniques for hypospadias have evolved over the years but the principles of any surgery remain the same; namely, to give the child a straight penis with a terminal or near terminal meatus which is cosmetically and functionally acceptable with minimal morbidity. Hypospadias repair has a long and flat learning curve and requires patience, experience, and great enthusiasm to achieve acceptable results. The results published on the various operative techniques need to be repeated and validated by other surgeons, and long-term results (up to adulthood) are essential to justify operative methods and identify late complications^[4].

Proximal hypospadias defects represent the most challenging and complex manifestations of this entity and might be successfully treated with one of several one- or two-stage repairs^[5]. Each technique, whether two stage or one-stage, has its advantages and drawbacks and not one technique has gained widespread popularity. Heralding one technique as the gold standard for posterior hypospadias is probably unrealistic and surgeons have to master a variety of techniques because various patient-related specifics can favor one or another technique^[6].

Surgical techniques commonly used to repair hypospadias includes Single stage repair such as Tubularised incised plate urethroplasty, Byars flaps and Bracks's Two stage repair. After the urethral plates are transected, the options are the one stage and two stage procedures. Because the management has yet not been standardized, surgeons choose a technique with which they are comfortable. One-stage repair has been a conventional treatment of hypospadias with its advantages of less extensive surgery and lower cost. Examples are the TIP urethroplasty, modified Koyanagi repair and the onlay repair. In recent years, there has been renewed interested in treating those severe cases with two-stage repair. Although the two-stage procedures are more time-consuming and more costly, they usually provide a healthier urethral bed and less scar tissue around the urethra. Some surgeons prefer single-stage urethroplasty whereas others advocate two-stage repair to achieve better functional and cosmetic outcome. The overall complication rates of one stage and two stage procedures were similar, although the types of complication were different. Hence the above study is conducted to compare Single with two-stage Repair of hypospadias with regard to the outcomes and complications.¹

There are many surgical procedures described for the repair of hypospadias and none is superior to the other. There are probably more than 200 reported original methods of urethral reconstruction. The aim of hypospadias surgery is not only to achieve a functional penis but also a normal cosmetic appearance. The most common repairs to correct hypospadias are Bracka's two stage repair, Mathieu's repair, meatal advancement and glanuloplasty incorporation (MAGPI) and tubularized incised plate (TIP) urethroplasty. The cause of hypospadias is still not certain and is controversial. Its treatment remains demanding as well as challenging. Complications are frequent which makes management frustrating. Considering the increasing number of patients with hypospadias coming to our OPD we conducted a study comparing Single stage TIP urethroplasty and two stage urethroplasty for hypospadias.

Objectives:

To compare single and two stage repair of hypospadias with respect to Operative Time, outcome, complications, post operative follow up.

MATERIALS AND METHODS

A prospective study was carried out in ESIC MC PGIMSR Rajajinagar, Bengaluru from January 2019 to June 2020 on comparison of single and two stage repair of hypospadias. Inclusion criteria were the patients who were willing to give written and informed consent and patients with hypospadias of all age group. Exclusion criteria was repair of failed hypospadias. A proforma drafted for the study of all patients with Hypospadias was used. Computer based randomization using random number tables was done. Diagnosis was done by history, clinical examination, Routine investigations and Ultrasound examination. 50 cases were studied during the study period (January 2019 to June 2020).

Patients were divided into two groups one undergoing One stage repair- TIP urethroplasty and other into two stage repair groups-Bracka's repair using computer generated randomization. Surgical outcome was assessed using Hypospadias Objective Score Evaluation (HOSE) scoring. It is a validated five-point scoring system that incorporates five domains: meatal location and shape, urinary stream, straightness of erection, and presence and complexity of urethral fistula^[15], for a total score of 5 to 16 points. In the original description of HOSE, a total score of ≥ 14 points indicated an acceptable outcome after hypospadias repair.^[15]

Statistical Analyses

The data collected were entered into excel spread sheet and was analyzed using Statistical Package for Social Science (SPSS). Descriptive statistics with frequency, percentage, mean and standard deviation will be taken. p-value will be taken as significant when < 0.05 . Chi Square Test was used to assess the statistical significant difference.

The formula for the chi-square statistic used in the chi square test is:

$$\chi^2 = \sum \frac{(O_i - E_i)^2}{E_i}$$

Chi-square (χ^2), the subscript "c" are the degrees of freedom. "O" is observed value and E is expected value.

Sample size

A total of 50 cases. On the basis of previous literature, the variance ratio between two different types of treatment is 1.85. χ^2 tests - Variance: Difference from constant. Calculated sample size was 47, which was rounded of to 50 after considering 10% dropout through surgery.

Surgical technique:

Surgical management of hypospadias includes straightening ventral curvature (Dorsal Plication, Ventral Corporal lengthening) and urethroplasty. All hypospadias can be repaired using either of two operative techniques:

1. TIP (Most Common – One Stage Repair)
2. Two-stage graft urethroplasty.

We performed Tubularized Incised Plate urethroplasty (TIP) in one stage repair group and Bracka's procedure in two Stage repair group. In one stage repair (TIP) a skin flap is marked on the distal penile shaft for the creation of a flap-based distal urethral reconstruction. The flap is rotated 180° and sutured into incisions on either side of the glanular groove and up to the tip. The prepuce is divided and mobilised until an outer cover is achieved. The catheter is kept postoperatively for 5 days. In two Stage Repair (Bracka's Technique) (a) orthoplasty is commenced through a circumferential incision 3 mm from the coronary sulcus with division of the prepuce dorsally. On the ventral side, the fibrous chordee is divided and partially excised, the plane of preparation being the underlying fascia. (b) The new position of the meatus is secured with a single suture and the dorsal flaps are rotated to cover the ventral defect. A urinary catheter remains in place for 3 to 4 days postoperatively. (c) Stage two comprises urethral reconstruction, which is to be performed 6 months after the stage one procedure. A U-shaped incision is made just proximal to the meatus, terminating on either side of the glans. (d) The inner lining is closed in two layers around a urinary catheter. A waterproofing technique is used to minimise the risk of fistula formation. (e) The outer lining is also closed in two layers.. The urinary catheter remains for 5 to 6 days postoperatively.

RESULTS

The study population included 50 patients who were divided into two groups with 25 in each, undergoing one stage repair and two stage repair using computer generated randomization. Results were expressed as means \pm standard deviation of the means, minimum, maximum or number (%). Comparison between the two groups was done with respect to operative time, outcome, complications, post operative follow up.

As regarding age, it ranged from 1 to 5 years in one stage group and 1 to 6 years in two stage group. We performed the one stage repair to children with mean age of 2.83 ± 1.17 and two stage repair to children with mean age of 3.21 ± 1.15 .

Table [1]: Age distribution

	One stage repair group	Two stage repair group	p-value
Study group	25	25	-
Age group	1-5 years	1-6 years	-
Mean \pm SD	2.83 ± 1.17	3.21 ± 1.15 years	0.637

As regarding operative time, in one stage repair group it ranged from 150-300 mins (Mean \pm SD 193.5 ± 41.84). Operative time in two stage repair group ranged from 120-250 mins (Mean \pm SD 180.5 ± 32.60) and 140-280 mins (Mean \pm SD 196.0 ± 27.72) in first and second stages respectively. No significant association was found among the spirometry pattern and the gender.

Table [2]: Operative time (minutes) in the studied patients.

Procedure	Time (mins)	Mean \pm SD
One stage repair	150-300	193.5 ± 41.84
Two stage repair		
Stage I	120-250	180.5 ± 32.60
Stage II	140-280	196.0 ± 27.72

As regarding complications, we were able to detect bleeding, infection, wound dehiscence, fistula, stricture, meatal stenosis and diverticula.

Table.[3]. Complications in distal hypospadias

Complications	One stage repair group	Two stage repair group	p-value
i) Bleeding	1	1	1
ii) Infection	2	2	1
iii) Dehiscence	1	1	1
iv) Fistula	1	0	0.307
v) Stricture	0	1	0.307
vi) Meatal stenosis	2	1	0.539
vii) Diverticula	1	1	1

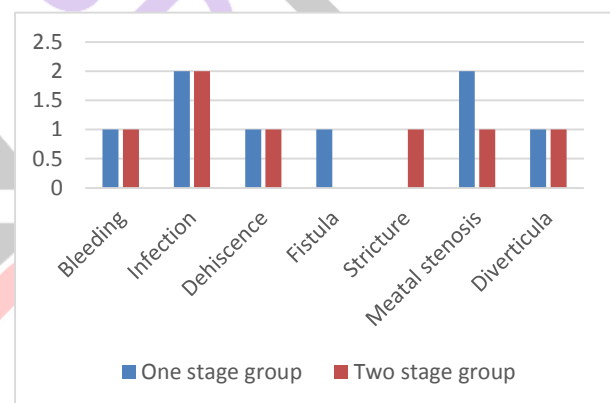


Table.[4]. Complications in mid shaft hypospadias.

Complications	One stage repair group	Two stage repair group	p-value
i) Bleeding	2	1	0.514
ii) Infection	1	0	0.299
iii) Dehiscence	1	1	1
iv) Fistula	2	1	0.514
v) Stricture	3	1	0.236
vi) Meatal stenosis	2	0	0.126
vii) Diverticula	3	1	0.236

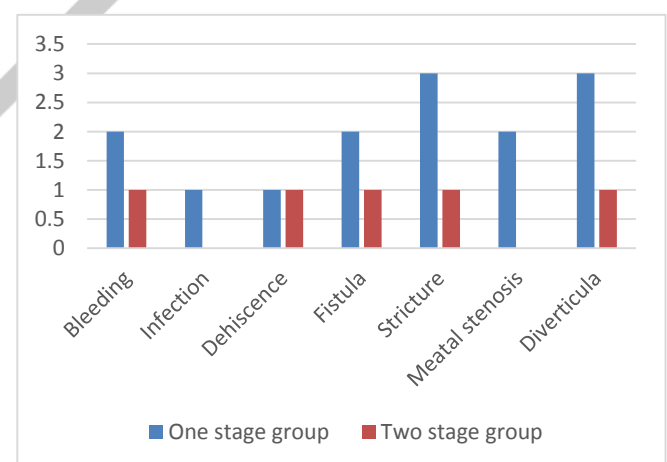
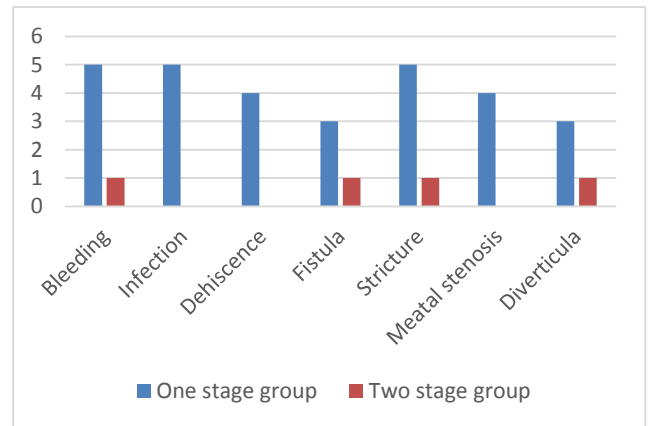


Table.[5]. Complications in proximal hypospadias

Complications	One stage repair group	Two stage repair group	p-value
i) Bleeding	5	1	0.009
ii) Infection	5	0	0.001
iii) Dehiscence	4	0	0.009
iv) Fistula	3	1	0.196
v) Stricture	5	1	0.009
vi) Meatal stenosis	4	0	0.009
vii) Diverticula	3	1	0.196



As regarding surgical outcome, we used HOSE scoring system. In one stage repair group, eleven and five patients in distal and mid shaft hypospadias respectively and one patient in proximal hypospadias had HOSE score in 14 to 16 range. And two patients each in distal and mid shaft hypospadias and four patients in proximal hypospadias had HOSE score less than 14. In two stage repair group, twelve and five patients in distal and mid shaft hypospadias respectively and four patients in proximal hypospadias had HOSE score in 14 to 16 range. And one, two and one patient each in distal, mid shaft and proximal hypospadias had HOSE score less than 14.

Table.[6]. HOSE scoring in the studied patients.

Hypospadias	Procedure	14-16	<14	p-value
Distal	One stage repair	11	2	0.587
	Two stage repair	12	1	
Midshaft	One stage repair	5	2	1
	Two stage repair	5	2	
Proximal	One stage repair	1	4	0.158
	Two stage repair	4	1	

As regarding post operative follow up, In one stage repair group, the mean follow up time in months was 6.15 ± 2.53 , it ranged from 2-10 months. In two stage repair group, the mean follow up time in months was 12.22 ± 4.30 , it ranged from 6-18 months.

Table.[7]. Post-operative follow up in months.

Procedure	Follow up(months)	Mean \pm SD	p-value
One stage repair	2-10	6.15 ± 2.53	0.018
Two stage repair	6-18	12.22 ± 4.30	

DISCUSSION

The present study is aimed at comparing single and two stage repair of hypospadias with respect to post-operative complications, surgical outcome and post-operative follow up. One stage repair group underwent TIP urethroplasty and two stage repair group underwent Bracka’s repair. According to Bracka, one of the major advantages of staged repair is the possibility to achieve a good cosmetic result with placement of the urethra deep in the glans and creation of a natural slit-like meatus. Accordingly, most series report an excellent cosmetic results and patient satisfaction^[9]. DC Zheng et al^[8] concluded that in the single- stage group, the complication rates between the cohorts were significantly different, whereas no difference was observed between the

two cohorts in the two- stage group. Future research should focus on a prospective random controlled trial with different urethroplasties for treating proximal hypospadias with severe chordee. The overall complication rates of the single- stage urethroplasty and the two- stage urethroplasty were not statistically different, stricture, a rather severe complication, appeared at a higher rate in the single- stage group. Therefore, we believe that the two- stage urethroplasty is preferred for treating proximal hypospadias with severe chordee after correction via urethral plate mobilization and transection^[8].

In our study, post-operative complications were insignificant between the two groups in Distal and Mid Shaft Hypospadias, but in Proximal Hypospadias, one stage repair had significantly higher complications when compared to two stage repair using Brack's repair. Surgical outcome assessed by HOSE score had an acceptable outcome (total HOSE score 14-16) in one stage repair for distal and midshaft hypospadias with restriction (total HOSE score <14) in proximal hypospadias, whereas in two stage repair group, all types of hypospadias had an acceptable outcome (total HOSE score 14-16). Mean postoperative follow up period was shorter in one stage repair group in comparison with two stage repair group. Table[8] shows Brack's two stage repair has one of the least complication rates for the repair of proximal hypospadias. Table [9] shows complication rates of Brack's two stage repair of present study in comparison with other studies conducted in the past.

Table.[8]. Comparison of complication rates of different techniques for proximal hypospadias

Procedure	Complication rates
Original Koyanagi	45-50%
Modified Koyanagi	16-30%
Duckett- Asopa	42%
Onlay	31-45%
Snodgrass	30%
Bladder mucosa graft	66%
Buccal mucosa graft	32-39%
Two stages (Brack- Cloutier's)	13%

Table [9]: Complication rates in studies on Brack's two stage repair.

Author	Bleeding	Infection	Dehiscence	Stenosis	Fistula	Stricture	Diverticulum	Complication	Success
Bracka, et al	-	-	-	15%	15%	-	-	30%	70%
Khan et al	4.4%	4.2%	4.2%	5.6%	38.8%	9%	9%	66.9%	33.1%
Greenfield et al	-	-	-	16%	39%	19%	16%	61%	39%
Joshi et al	-	-	-	-	21%	7%	7%	36%	64%
Altarac et al	-	-	-	-	7%	3%	-	10%	90%
Sadeghi et al	5%	20%	-	5%	40%	10%	-	40%	60%
DC Zheng et al	-	-	-	12%	21%	8%	-	46%	54%
Our study	12%	12%	8%	4%	8%	12%	12%	16%	84%

LIMITATIONS

This study is subject to selection bias, since patients were selected from the inpatients of a single tertiary hospital. Therefore, the results might not represent the general population.

CONCLUSION

One stage repair is a good choice due to its simplicity, lower complication rate with good cosmetic results and shorter follow up in distal and mid shaft hypospadias. The two stage repair is a safe and reliable approach in all types of hypospadias. The procedure can be accomplished with a low-complication rate and with a good final cosmetic result in proximal hypospadias compared to one stage repair.

REFERENCES

1. Raimund Stein. Hypospadias. *European Urology Supplements* 11 (2012) 33–45.
2. Leung ARC, et al. Hypospadias: an update. *Asian J Androl* (2007); 9:16–22.
3. Lisa Steven, et al. Current practice in paediatric hypospadias surgery; A specialist survey. *Journal of Pediatric Urology* (2013) 1477-5131.
4. Raimund Stein. Hypospadias. *European Urology Supplements* 11 (2012) 33–45
5. Rajendra Nerli, et al. Modified Koyanagi's procedure for proximal hypospadias: Our experience. *International Journal of Urology* (2010) 17, 294–296.
6. Alexis Arnaud, et al. Choosing a technique for severe hypospadias. *African Journal of Paediatric Surgery*. September-December (2011) / Vol 8 / Issue 3, (2011) , 286-290.
7. MK Hassan, et al. Single Stage Urethroplasty for Proximal Hypospadias with Chordee. *Faridpur Med. Coll. J.* (2011); 6(2): 66-69.
8. DaChao Zheng, HaiJun Yao, ZhiKang Cai, Jun Da, Qi Chen, YanBo Chen, Ke Zhang, MingXi Xu, MuJun Lu, Zhong Wang Two-stage urethroplasty is a better choice for proximal hypospadias with severe chordee after urethral plate transection: a single-center experience, *Asian Journal of Andrology* 2015;17(1):94–97
9. Bracka A. The role of two-stage repair in modern hypospadiology. *Indian journal of urology: IJU: journal of the Urological Society of India.* 2008 ;24(2):210.
10. Alexander Springer et al. Split Dorsal Dartos Flap Transposed Ventrally as a Bed for Preputial Skin Graft in Primary Staged Hypospadias Repair, *UROLOGY* (2012) , 79: 939–942.
11. Haxhirekha KN, Castagnetti M, Rigamonti W, Manzoni GA. Two-stage repair in hypospadias. *Indian journal of urology: IJU: journal of the Urological Society of India.* 2008 ;24(2):226.
12. Joshi RS, Bachani MK, Uttarwar AM, Ramji JI. The Bracka two-stage repair for severe proximal hypospadias: A single center experience. *Journal of Indian Association of Pediatric Surgeons.* 2015 ;20(2):72.
13. Shukla AK, Singh AP, Sharma P, Shukla J. Two stages repair of proximal hypospadias: Review of 700 cases. *Journal of Indian Association of Pediatric Surgeons.* 2017 ;22(3):158.
14. Singh AP, Shukla AK, Sharma P, Prasad R. One-Stage repair of hypospadias using the modified prepuccial island flap technique: Experience with 200 cases. *Archives of International Surgery.* 2016 ;6(2):121.
15. Holland AJ, Smith GH, Ross FI, Cass DT. HOSE: an objective scoring system for evaluating the results of hypospadias surgery. *BJU Int.* 2001 Aug; 88(3): 255-8.