

# A Surgical Approach For The Management Of Intraosseous Defect In The Posterior Teeth Using Composite Grafting

<sup>1</sup>Dr. Shilpi Shah, <sup>2</sup>Dr. Mishal Shah, <sup>3</sup> Dr. Priyanka Kacha

<sup>1</sup>Professor and Head of the department, <sup>2</sup>Reader, <sup>3</sup>Post Graduate Student

<sup>1</sup>Department of Periodontics and Oral Implantology,

<sup>1</sup>Ahmedabad Dental College and Hospital, Gandhinagar, India

**Abstract:** So far, various methods have been used to accelerate the bone healing process. Among these methods is platelet-rich plasma (PRP) or platelet concentrate (PC), which provides high concentrations of growth factors. This case presents regeneration of intraosseous defect by adjunctive use of along (Hydroxyapatite bone graft) with PRF open flap debridement grafted in Mandibular first molar. Hydroxyapatite is the major mineral component in bone, and synthetic apatite has become a common osteoconductive replacement material also, because of the internal architectural design of the scaffolds, for bone defects. Gain of clinical attachment was found as the healing of periodontal defect. Platelet-rich fibrin (PRF) is a leukocyte and platelet preparation that concentrates various polypeptide growth factors and therefore has the potential to be used as regenerative treatment for periodontal defects. Growth factors in general and PRF in specifically are part of new biotechnology with already established efficacy and future potentials. The potential of PRF in periodontal surgery for regeneration of intraosseous defects in chronic periodontitis patients should be further studied.

**Key Words:** PRF, Hydroxyapatite, Osteoconductive, intraosseous defect

## I. INTRODUCTION

Periodontitis involves an inflammatory process, of bacterial origin, affecting the periodontal tissues and producing the destruction of the supporting tissues to the teeth. The main aim of periodontal therapy is to treat the infection caused by periodontal pathogenic biofilm and to arrest or slow down further attachment and bone loss, ultimately preventing tooth loss. The bone loss related with periodontal ailment is vertical in nature, creating gutters of bone loss, there can be a possibility to regenerate periodontium. Regenerative strategies most usually appoint surgical placement of membranes or bone graft materials.

Bone graft can aid in bone regeneration by 3 specific methods, which include:<sup>[1]</sup>

- i. Osteogenesis
- ii. Osteoconduction, and
- iii. Osteoinduction.

Hydroxyapatite (HA) shows high degrees of biocompatibility, provides proper support for cellular activity, stimulates ossification through osteoconduction, and it is the major inorganic component of the bone matrix, and synthetic hydroxyapatite when used as a bone graft<sup>[2]</sup>.

Platelet Rich fibrin (PRF) is particular composition of an immune and platelet concentrate, 3-D structure, and related biology that collects all of the ingredients of a blood pattern for healing of wounds and immunity. PRF consists of a number of growth factors like platelet derived growth factor (PDGF), transforming growth factor  $\beta$ 1 (TGF  $\beta$ 1), insulin like growth factor (IGF), etc., revealing varied compelling local properties such as cell migration, cell attachment, cell proliferation, and cell differentiation<sup>[3]</sup>.

It has been studied that (PRF) slowly released autologous growth factors which are greater outcome for the proliferation and differentiation of osteoblasts. Regarding the effect of PRF on bone healing, research have mentioned the effect of PRF on implant healing and stability<sup>[4]</sup>.

*Gassling et al.* explained in their study that PRF membranes are suitable for cultivation of periosteal cells for bone tissue engineering.

*Pradeep et al.* in their study concluded that when HA is mixed with PRF, it increases the regenerative effects observed with PRF in the treatment of human three wall intrabony defects<sup>[3]</sup>.

In this report, the left mandibular first molar demonstrated intrabony defect after debridement alloplast and PRF mixed and placed. Clinically and radiographically changes recorded.

## II. CASE REPORT

A 30-years-old female patient came to the Department of Periodontics with a chief complaint of food lodgment in the lower left back teeth region. The patient had no medical history.

In the mandibular left posterior teeth, there were horizontal defects, and the mandibular left first molar had a vertical defect. 36 had a PPD of 6 mm. Thereby surgical intervention was necessary and open flap debridement with regenerative therapy using a combination of PRF, Bone graft (BG)- alloplast was planned in relation to 36 tooth region.

The treatment plan including of scaling and root planing followed by flap surgery with consist of regenerative materials for intrabony defects. Patient was advised 0.2 % chlorhexidine mouth rinse twice daily. After six weeks of phase-I therapy, the patient was recalled and the clinical parameters have been re-evaluated.

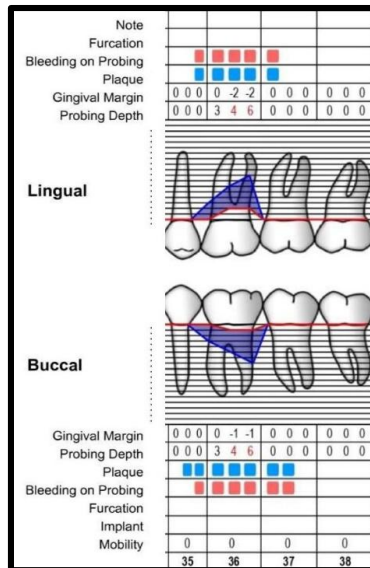


Fig:1 Periodontal charting art. 35, 36, 37

**PRF Preparation**

The PRF was prepared in accordance with the protocol developed by Choukroun *et al.* [5]. On the day of surgery, intravenous blood was collected in the 10 ml of the sterile tube without addition of anticoagulant and centrifuged immediately. Blood was centrifuged utilizing a tabletop centrifuging machine for 12 min at 2,700 rpm.

The resultant product consists of three layers:

1. Topmost layer contain acellular platelet poor plasma (PPP).
2. PRF clot in the middle.
3. Red blood cells (RBCs) at the bottom.

Following the removal of PPP, PRF was simply removed from RBCs using a sterile tweezer and then placed directly into the sterile dampen dish. The PRF was then mixed with alloplast bone graft [6].

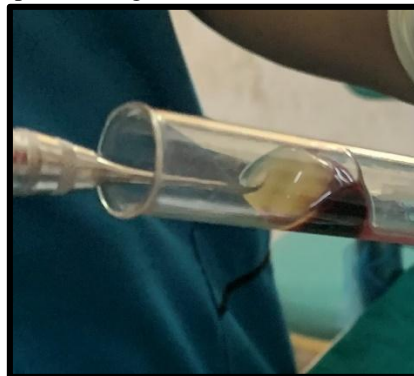

Fig: 2 PRF prepared

Local anesthesia was administrated, sulcular incision were placed and elevation of full thickness flap in relation to 35, 36, and 37. The area was debrided of subgingival calculus and granulation tissue. Width and depth of the intra bony defect was measured using UNC 15 probe. Alloplast Bone graft was mixed with PRF. Debridement of granulation tissue was done followed by sterile saline irrigation. The required amount of mixed graft material was taken and made into dough form and adapted to the defect. Over the grafted defect, compressed membrane trimmed and adapted. This was followed by the approximation of facial and lingual flaps using simple interrupted sutures [Fig.9]. Periodontal dressing (Non-eugenol pack) was placed.

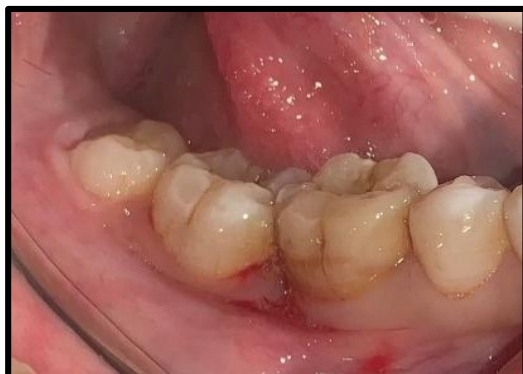

Fig:3 Pre-operative

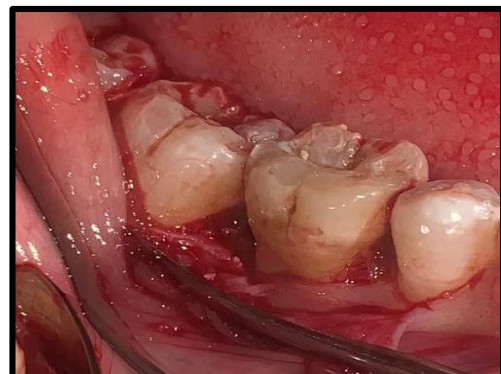
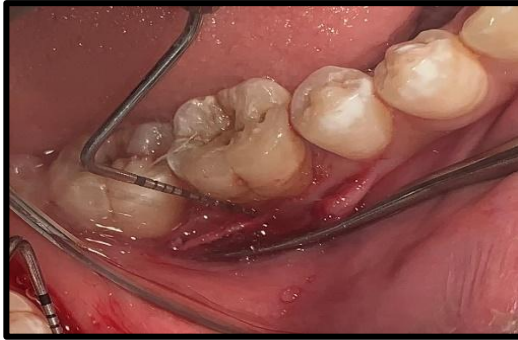
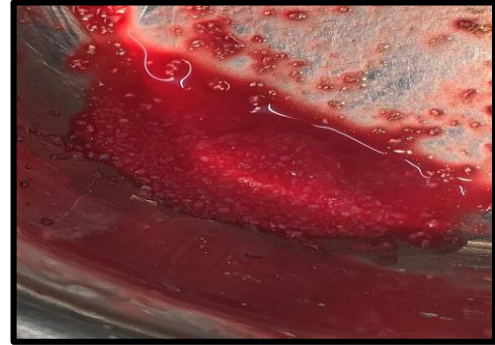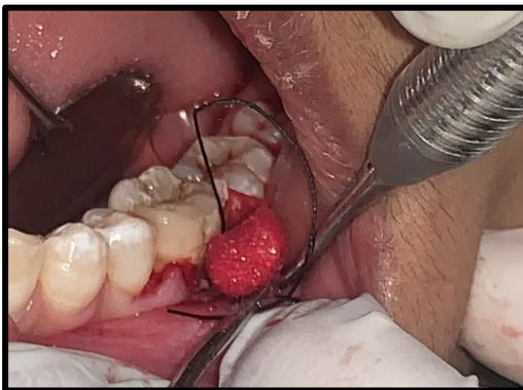
Fig:4 Full thickness flap



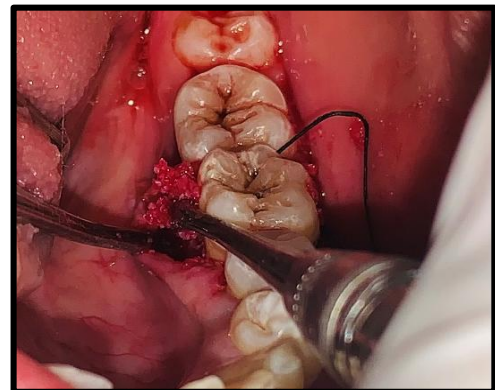**Fig:5 Defect measured**



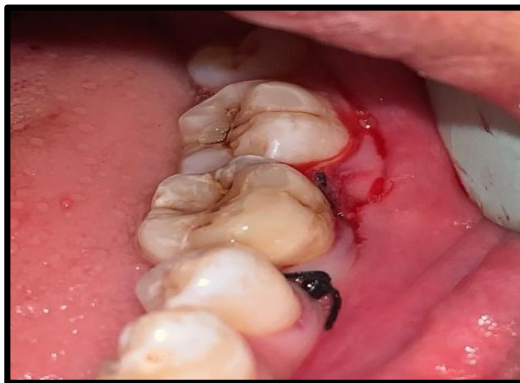**Fig:6 PRF+ Bone graft**



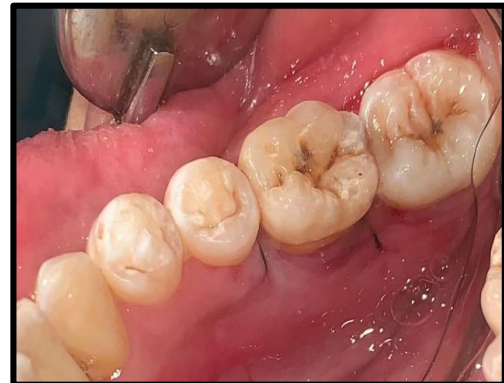**Fig:7 Bone graft placement (buccal)**



**Fig:8 Bone graft placement (lingual)**



**Fig:9 Suturing**



**Fig:10 completed sutures**

The patient was instructed postoperative instructions and on maintenance therapy. The postoperative readings for probing depth were made after 6 months. The results suggested significant improvements with the gingival presentation being normal in colour, absence of swelling, and probing depth reduced to 1-2 mm in all areas. Probing depth was recorded to be 2 mm in the mandibular region following the periodontal regenerative therapy. Radiographically, the vertical defect was found to be exterminated.

**Radiographic assessments of percentage bone fill**

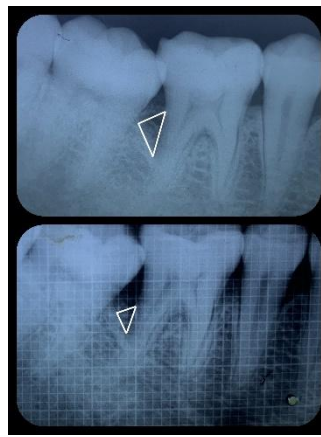
Intra-oral periapical radiographs of each defect site with millimeter grid in place were obtained using long cone/paralleling radiographic technique.

Radiographs were taken at baseline, 3 months, 6 months and 9 months and were measured with the help of the formula:

- A. Pre-operative intrabony component (valueA) =  

$$\frac{\text{Cemento Enamel Junction (CEJ) to Bone depth} - \text{CEJ to Alveolar crest}}{\text{CEJ to Root apex}} \times 100 \quad \text{Eq.1}$$
- B. Post-operative intrabony component(valueB) =  

$$\frac{\text{CEJ to Bone depth} - \text{CEJ to Alveolar crest}}{\text{CEJ to Root apex}} \times 100 \quad \text{Eq.2}$$
- C. Amount of bone fill = Value A – Value B Eq.3
- D. Total percentage of bonefill = Amount of bone fill / Pre-operative intrabony component Eq.4



**Fig.11 Pre and Post-operative radiograph**

### III. DISCUSSION

The four crucial factors that impact bone regeneration after the periapical surgery are number one wound closure, angiogenesis as a blood supply and source of undifferentiated mesenchymal cells, space maintenance, and stability of the wound (PASS principle). There are many studies that have proved the efficacy of DBM as a successful regenerative material. HA has proven advantageous results with respect to periodontal regeneration in periapical defects.

Reduction in PD, IBD and gain in CAL are the major clinical outcomes measured to determine the success of any periodontal treatment. When compared to baseline and 9 months, all three groups in the current study showed a substantial decrease in PD and CAL growth. The first author to focus attention on the morphology of the bone defect, and on the importance of its careful debridement was **Prichard in 1957**. He reviewed bone regeneration to be actual and predictable objective in treatment, and provided a careful selection of cases according to the bone morphology of the defect is created.

The deliberated role of the PRF membrane in our case report was to contain the HA and PRF in the bony defect in the early phase of wound healing.

**Dohan D.M.** showed a gradual release of growth factors from PRF than PRP and perceived better healing properties with PRF. The procedure to acquire platelet rich plasma is to a greater extent complex than preparation of PRF. Thus, there are obvious advantages of PRF over PRP<sup>[5]</sup>.

**According to Sharma A. et al.** in randomized controlled clinical trial of three wall intrabony defects in patients with chronic periodontitis acquired greater bone fill at sites treated with PRF and conventional open-flap debridement in relation to conventional open-flap debridement alone<sup>[5]</sup>.

### IV. CONCLUSION

Within the limits of this study indicate that Hydroxyapatite could be successfully used with or without PRP for intrabony defect in dentistry. On the basis of the results obtained in our case report, we hypothesize that the use of PRF in together with HA crystals might have improved the resorption of the graft crystals and would have promoted the rapid rate of bone formation. Addition of PRF in the Hydroxyapatite graft material can be understood with faster and better consolidation of graft material and a higher osseointegration. Growth factors in general and PRF in specifically are part of a new biotechnology with already established efficacy and future potentials. It is the responsibility of the clinician to gain a thorough understanding of this biotechnology and to use it efficaciously and accurately for the benefit of patients.

### V. REFERENCES:

- Balaji VR, Manikadan D, Ramsundar A. Bone graftin periodontics. Matrix Sci Med. 2020;4: 57-63
- Ahmad Mogharehabet, Faegheh Fazeli, Zohreh Afshari, Jaber Yaghini (2020). "Effects of L-PRF and Advanced PRF Plus with Hydroxyapatite/Beta Tricalcium Phosphate in Bone Regeneration-A Histologic and Histomorphometric Study in Rabbits", International J of Pharmaceut and Phytopharmacological Research, 10(4), pp.204-211.
- Shivashankar VY, Johns DA, Vidyanath S, Sam G. Combination of platelet rich fibrin, hydroxyapatite and PRF membrane in the management of large inflammatory periapical lesion. J Conserv Dent 2013;16:261- 264.
- Abd Rabbouh AI, Mwafey IM, Abo Zaid FA, Mohammed AK. Evaluation of Nanocrystalline Hydroxyapatite Plus Platelet-Rich Fibrin as A Grafting Material Around Dental Implant After Narrow Alveolar Ridge Splitting. Al-Azhar Assiut Dental Journal. 2021 Oct 1;4(2):179-87.
- Choukroun J, Adda F, Schoeffer C, Vervelle A. PRF: an opportunity in perio-implantology (in French). Implantodontie 2000;42:55–62.
- Pradeep AR, Bajaj P, Rao NS, Agarwal E, Naik SB (2012) Platelet-rich fibrin combined with a porous hydroxyapatite graft for the treatment of three-wall intrabony defects in chronic periodontitis: a randomized controlled clinical trial. J Periodontol.
- Katuri KK, Kumar PJ, Swarna C, Swamy DN, Arun KV. Evaluation of bioactive glass and demineralized freeze dried bone allograft in the treatment of periodontal intraosseous defects: A comparative clinico-radiographic study. J Indian Soc Periodontol. 2013;17:367–72