

Parotidectomy by Modified Blair's incision: Our experience at tertiary care center

¹Dr. Chandani D. Bhatt (M.S. ENT), ²Dr. Ishita Shah (M.S. ENT), ²Dr. Niraj Modi (M.S. ENT)

Abstract :

Background : parotid gland is affected by both benign and malignant disease, more with benign disease which include pleomorphic adenoma. Both superficial and deep parotidectomy, total parotidectomy or extra capsular parotidectomy with or without neck dissection is being performed routinely. Different incision like Blair's, modified Blair, face lift, retro auricular with face lift, cervical incision has been used but most widely used is modified Blair's incision.

Material and Method : retrospective study aim to find outcome and usefulness of modified Blair's incision in parotid surgery
Result : it shows that modified Blair's incision gives better post operative outcome in terms of scar mark, and complications.

Keyword : parotidectomy, Modified Blair's incision

INTRODUCTION

Parotid gland is major saliva gland and its disorders include a heterogeneous group of congenital, inflammatory and neoplastic diseases that may have a focal or diffuse pattern of presentation. Benign diseases are more prevalent than malignant one and are encountered in our daily OPD. Pleomorphic adenoma is the most prevalent benign parotid tumor, but it shows potential malignancy and carcinoma ex-pleomorphic adenoma that occurs in 3-15% of pleomorphic parotid adenoma patients. Multiple surgical options for incision pattern exist for parotid tumors to decrease the facial scar mark, and post operative complications and other cosmetic complications. The most commonly used incisions for parotidectomy are the Blair incision which was modified by Bailey and widely used now-a-days. There are increasing evidences for the use of extracapsular dissection as judged by the minimum fascia-tumor distance for removal of superficial for benign parotid tumors.

OBJECTIVES

The current retrospective study aimed to use of Modified Blair's incision in parotidectomy.

METHODS

This study was conducted in patients presenting with painless, slow-growing mass in the parotid region were vulnerable to evaluation. Patients with freely mobile parotid lesions were subjected to ultrasonographic examination to define lobe of involvement of lesions and then subjected for fine needle aspiration cytology to confirm the nature of lesions whether benign or malignant. The study included all patients with parotid lesions of grade zero on House-Brackmann facial nerve grading system. Sample size calculation showed that 50 cases are valuable for getting a conclusive outcome. All surgeries were performed under general anesthesia. Parotidectomy was performed through a Modified Blair's incision which runs behind the tragus and down onto the neck 3 cm below the mandibular margin and along the natural skin crease. A skin flap was elevated out over the parotid, dissection was carried down to identify the main trunk of the facial nerve and continued to identify its main branches during mass dissection. Once the superficial part of the gland including the tumor was removed, bed hemostasis was carried on cautiously to guard facial nerve branches, posterior branch of greater auricular nerve was spared and parotid duct was assured to be continent. Wound bed was drained by suction drain and wound was closed in layers to assure complete coverage of the bed with adequate hemostasis. Operative data included operative time, and intraoperative blood loss and complications were recorded.

Postoperative care

The facial nerve functions were evaluated according to House-Brackmann facial nerve grading system. Evaluation of facial nerve status was performed after patient was fully conscious. Postoperative (PO) collected data included duration of hospital stay, wound drainage and PO complications. After home discharge, all patients were asked to attend the outpatient clinic on the POD-7 for suture removal and to assess facial nerve function.

RESULTS

27 males and 23 females of mean age of 36(±5) were enrolled in the study. All were fresh swellings, but all patients had House-Brackmann grade 0 at presentation. All surgeries were conducted within a mean operative time of 3 hours. Mean intraoperative blood loss was 150ml (±20); and no patient required blood transfusion. Post-operative complications including Frey's syndrome seen in 2 patients, wound gaping in 2 patients, low-output parotidocutaneous fistula in 1 patient, temporary House-Brackmann grade-2 facial weakness in 3 patients.

Table(1)- Demographic data of studied patients

Age(in Years)	Number of patients	Percentage (%)
31-40	10	20
41-50	16	32
51-60	14	28
61-70	07	14
>71	03	06
Total	50	100

Table (2)- Clinical data and parameters

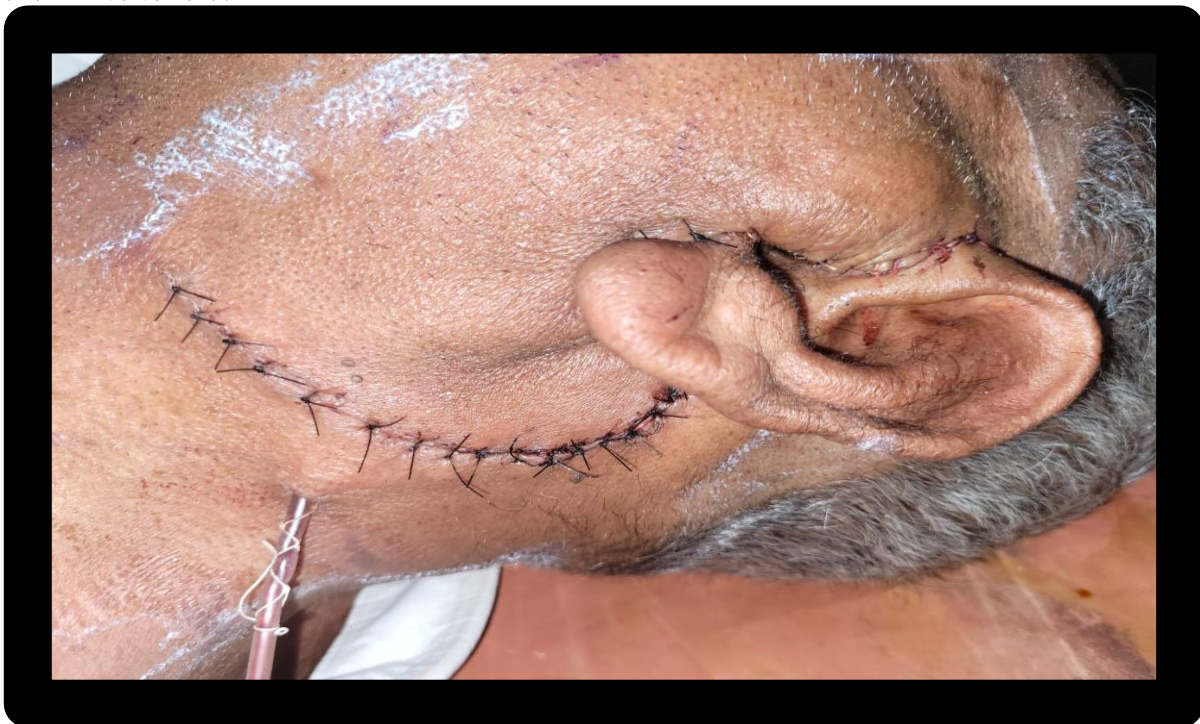Parameters	Range	Number (Percentage)
Operative time (minutes)	120 - < 150	22(44%)
	150-180	18(36%)
	>180	10(20%)
Intra- operative blood loss(ml)	<150 ml	42(84%)
	>150 ml	8(16%)
Hospital stay (days)	<4	41(82%)
	>4	9(18%)
Duration of Drain (days)	7	38(76%)
	8	8(16%)
	9	4(8%)

Table(3)- Post-Operative Complications

Complications	Number of patients	Percentage(%)
Facial Weakness(Temporary)	03	06
Skin Necrosis	01	02
Salivary cutaneous fistula	02	04
Wound Gaping	02	04
Frey's syndrome	03	06
Uneventful complications) (No)	39	78
Total	50	100

The follow up data was available for 50 patients. The patients were asked to grade the aesthetic appearance of the incision by grading them from 1 to 10 based on Visual analogue scale. The score up to 4 was considered as fair, a score from 4 to 7 was graded as good and a score more than 7 was considered as excellent. Majority of the patients graded the aesthetic appearance as good and excellent.

The tumors were removed in all the cases with no need for further skin extension. The patients presented good overall postoperative follow-up. The incisions showed highly satisfactory aesthetic results and only imperceptible scar could be seen after 2 months of the surgery. Only 01 case of local wound infection with dehiscence and blackening was seen in a patient with malignant parotid tumor with skin involvement .

**Figure 1- Modified Blair's incision starting behind Tragus.**

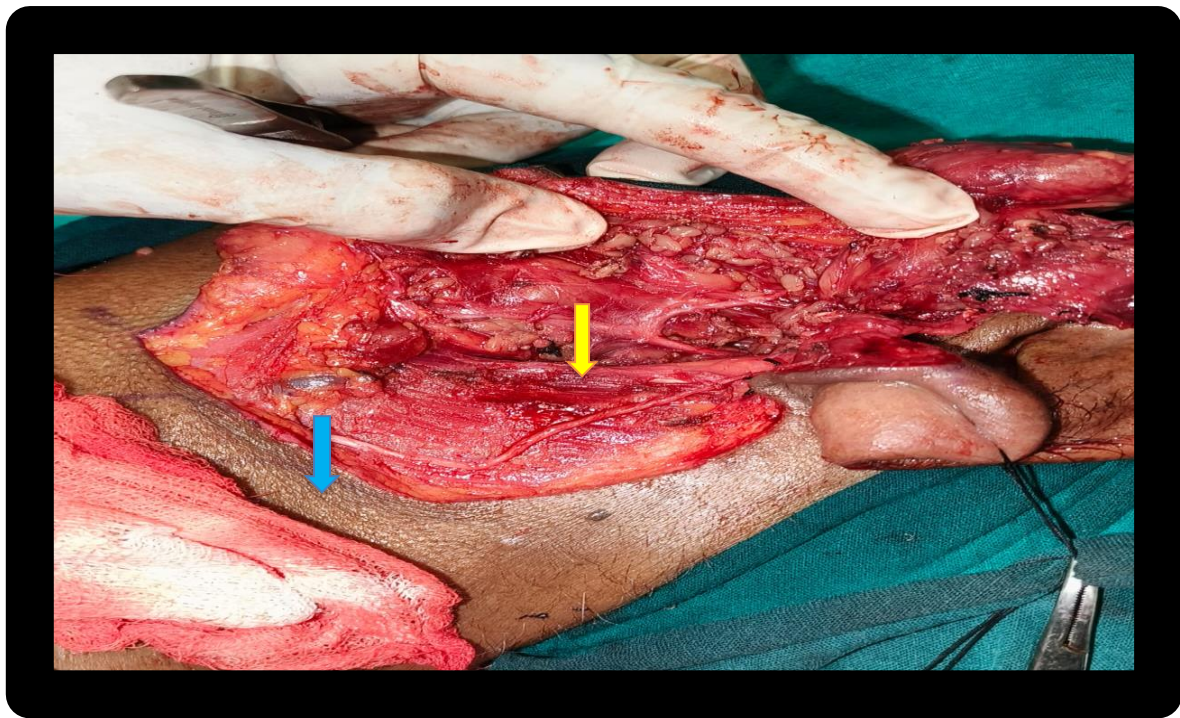


Figure 2- Intraoperative pictures of parotidectomy with blue arrow showing Greater Auricular nerve and yellow arrow showing trunk of Facial nerve.

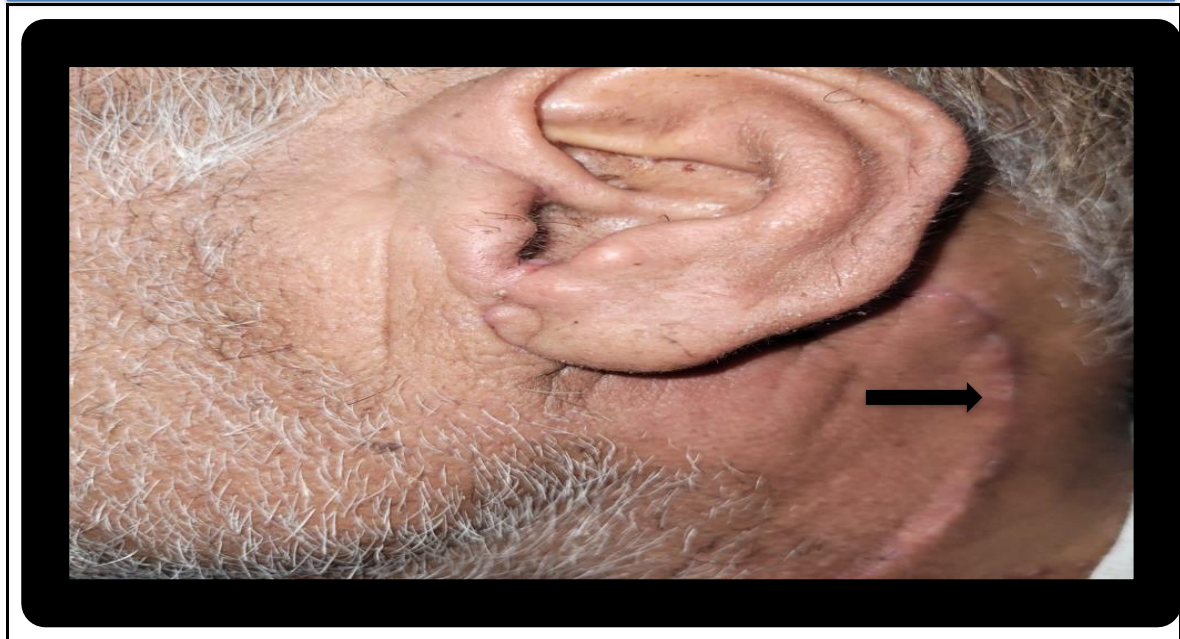


Figure 3 - Postoperative scar mark after 1 month of Surgery shown by black arrow

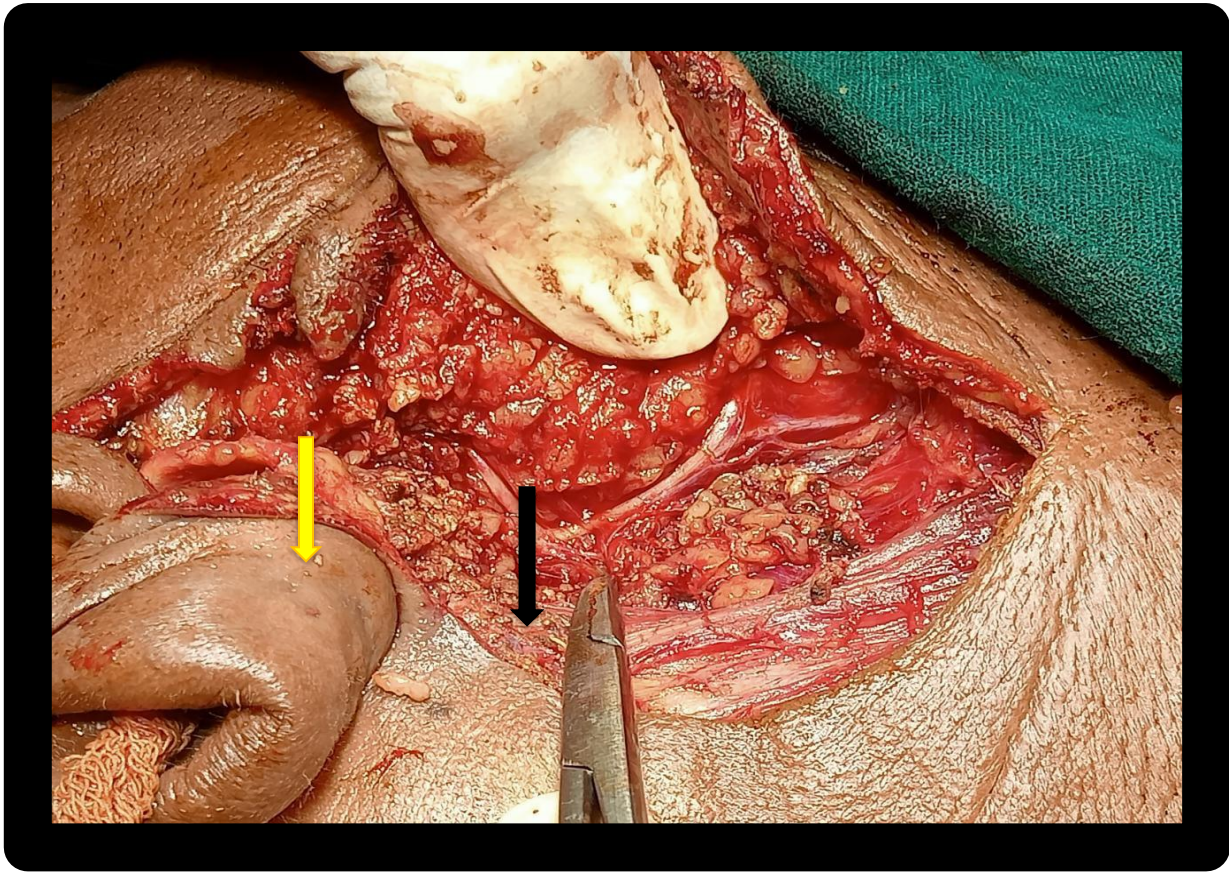


Figure 4- Intraoperative images showing Facial nerve trunk (Black arrow) and Tragal pointer (Yellow arrow)

DISCUSSION-

The obtained result of above study suggestive of Modified Blair's incision is useful in removing both benign and malignant tumours of parotid gland irrespective of size and the incision can be extended to include neck dissection. In context with tumour exposure and identification of facial nerve with reference to its anatomical landmark like tragal pointer and posterior belly of digastric muscle, this incision is very convenient. It has been observed that the incidence of post-operative complications like facial weakness, Frey's syndrome, subcutaneous fistula, skin necrosis, wound gaping etc. were less.

CONCLUSION

Modified Blair's incision is feasible, safe and give exposure to all nerve and vessels with least post-operative complications.

REFERENCES

1. Mlees M, Elbarbary A. Superficial or partial superficial parotidectomy for the treatment of primary benign parotid tumors. *J Surg Oncol.* 2020;122(7):1315-22.
2. Badger C, Michel M, Goodman J, Thakkar P, Joshi A. Minimum fascia tumor distance for selection of extracapsular dissection for benign parotid tumors: A preliminary study. *Am Otolaryngol.* 2021;42(1):102776.
3. House JW, Brackmann DE. Facial nerve grading system. *Otolaryngol Head Neck Surg.* 1985;93(2):146-7.
4. Lee DH, Yoon TM, Lee JK, Lim SC. Clinical features of pediatric parotid tumors: 10-year experience of a single institute. *Acta Otolaryngol.* 2013;133(11):1213-8
5. Martino M, Fodor D, Fresilli D, Guiban O, Rubini A, Cassoni A, et al. Narrative review of multiparametric ultrasound in parotid gland evaluation. *Gland Surg.* 2020;9(6):2295-311.
6. Kim J, Kim M, Choi S. High grade carcinoma ex pleomorphic adenoma of parotid gland: a case report. *J Korean Assoc Oral Maxillofac Surg.* 2020;46(5):348-52.
7. Matsumoto F, Ohba S, Fujimaki M, Kojima T, Sakyo A, Kojima M, et al. Efficacy of modified face lift incision for the resection of benign parotid gland tumor located anteriorly or superiorly. *Auris Nasus Larynx.* 2021;S0385-8146(21)00032-8.
8. Ton G, Lee L, Ng H, Liao H, Chen Y, Tu C, et al. Efficacy of laser acupuncture for patients with chronic Bell's palsy: A study protocol for a randomized, double-blind, sham-controlled pilot trial. *Medicine (Baltimore).* 2019;98(15):e15120.
9. Paolucci T, Cardarola A, Colonnelli P, Ferracuti G, Gonnella R, Murgia M, et al. Give me a kiss! An integrative rehabilitative training program with motor imagery and mirror therapy for recovery of facial palsy. *Eur J Phys Rehabil Med.* 2020;56(1):58-67.
10. Sun Z, Tian Y, Tan Y, Tao D, Li W, Ding J, et al. Effectiveness of Kinesio taping on peripheral facial paralysis: A protocol for systematic review and meta-analysis. *Medicine (Baltimore).* 2020;99(46):e23090.