

# Effectiveness of neural flossing in middle-aged group individuals with cervical radiculopathy

<sup>1</sup>Dr. A. K. VIJAY KRISHA KUMAR, <sup>2</sup>LAKSHMI BHARIA, <sup>3</sup>CHETANA.R

<sup>1</sup>Principal and Professor, <sup>2,3</sup>Intern  
Dr B. R. Ambedkar College of Physiotherapy  
Bangalore.

**Abstract-** Cervical Radiculopathy is a common clinical condition with a prevalence of 3.5 per thousand people and the annual incidence is from 83 cases to 210 cases per one lakh people with a peak of 50 to 59 years which is the result of compressive or inflammatory pathology from disc herniation, Spondylitic spur, or cervical osteophytes etc. The aim of the study is “To determine the effect of neural flossing technique in comparison to the standard treatment in patients with cervical radiculopathy”. A pre-test and post-test structured experimental study design was conducted using Convenience sampling with 40 participants, aged between 35-65 with Cervical Radiculopathy and assigned into a group of two where; Group A (Control group) received NFT along with Conventional therapy and Group B (Experimental group) received only Conventional therapy. A pre-post value was assessed using NPRS, NDI, Cervical ROM and Shoulder ROM. The result of this study depicted that the control group showed significant improvement in the outcome measures when compared to Conventional group. It was thus concluded that Neural Flossing Technique along with the standard treatment for Cervical Radiculopathy was found to be beneficial in reducing pain and improving Cervical and Shoulder mobility.

**Keywords:** Nerve Flossing Technique, Cervical Radiculopathy, Numeric Pain Rating Scale, Neck Disability Index, Cervical and Shoulder range of motion.

## I.INTRODUCTION:

Cervical radiculopathy is a prevalent musculoskeletal condition that affects a wide spectrum of groups, from desk workers to small-scale workers, from young students to elderly individuals. Cervical radiculopathy has an average yearly incidence rate of 83 per 100,000 individuals, with greater incidences occurring in the fifth decade of life (203 per 100,000)<sup>[1]</sup>.

Cervical radiculopathy is a disorder of the spinal nerve roots, and depending on where the affected roots are located, these lesions can trigger pain receptors in the soft tissues and joints of the cervical spine, which can cause sensory or motor changes in the upper extremity as well as loss of sensation, numbness, tingling, fragility in the upper-end point, motor defects in the neck and occasionally in the scapula, and pain along the nerve pathway into the hand and arm. Although approximately 5- 36% of individuals with cervical radiculopathy experience bilateral instances, the pain can radiate either unilaterally or bilaterally<sup>[2]</sup>. According to epidemiological studies, the C7 root (C6-C7 herniation), C6 root (C5-6 herniation), and C8 root (C7-T1 herniation) nerve roots are the most frequently afflicted<sup>[3]</sup>. Cervical traction, posture education, exercise, and manual therapy on the cervical spine are all frequent physical therapy methods used to treat cervical radiculopathy<sup>[1]</sup>.

The Neural flossing technique involves alternating between movements that involve at least two joints in combination, with one movement lengthening the nerve bed to exert greater tension on the nerve and the other simultaneously shortening the nerve bed to unload the nerve. This method has a variety of impacts, including physiologic, central, and mechanical effects including enhanced nerve excursion<sup>[4]</sup>. The mnemonic FLOSS sums up the general concepts of neural mobilization that ensure safe and effective treatment. Here, F denotes Fix the adjacent joint, L – Limit the ROM, O – Oscillate proximal or distal(or both) to the level of compression, S – Slow rhythmic motion, S – Symptom-free<sup>[5]</sup>. Michael Shacklock, proposed NFT as an active method that is a mechanically and physiologically helpful conservative treatment approach. This technique’s philosophy is based on the premise that the entire nervous system is a continuous structure that moves and slides in the body as we move, and that movement is related to necessary physiological processes. NFT moves the nerve through the tissues proximally and distally to the greatest degree feasible, moving every joint and body component that the nerve crosses. It’s akin to stretching one end of a cord while the other is slack and then switching directions<sup>[6]</sup>.

The main goal in treating cervical radiculopathy is to relieve pressure on the nerve root and enhance blood flow and oxygenation. The application of Neural flossing techniques may help in achieving this<sup>[7]</sup>.

Since NFT has been proven to be beneficial in treating neuropathic conditions such as carpal tunnel syndrome, low back pain, and other radiculopathies, it is believed that it may also be effective in treating cervical radiculopathy<sup>[8]</sup>. This

dissertation's main goal is to shed light on this topic and to make fresh, scientifically valuable contributions to knowledge<sup>[7]</sup>.

## II. OBJECTIVES:

### GENERAL OBJECTIVES

- To find out the effectiveness of Neural Flossing Technique in Cervical Radiculopathy patients.

### SPECIFIC OBJECTIVES

- To find out the effect of NFT in Cervical Radiculopathy patients in increasing the Range of motion.
- To find out the effect of NFT in Cervical Radiculopathy patients in reducing pain.

## III. METHODOLOGY:

**STUDY DESIGN:** Experimental study.

**STUDY SETTING:** Dr B.R. Ambedkar Medical College Department of Physiotherapy.

**SAMPLE SIZE:** 40 Samples.

**SAMPLING TECHNIQUE:** Convenient sampling technique.

### INCLUSION CRITERIA

1. Subjects between the ages of 35 to 65 years.
2. Subjects with Unilateral involvement.
3. Patients with positive Spurling's Test and Distraction test.
4. Patients with positive NPRS and NDI outcome measures.
5. Subjects diagnosed with pain radiating from the dorsum of the neck to the upper extremity.
6. Patients with pain intensity >5 measured with NPRS scale.
7. Patients with Median, Radial or Ulnar nerve involvement

### EXCLUSION CRITERIA

1. Recent trauma.
2. Patients with systemic disease.
3. Patients with congenital deformity.
4. Patients having cervical radiculopathy due to tumor.
5. Any infection or inflammation of the cervical spine.

### OUTCOME MEASURES

- NPRS ( Neck Pain Rating Scale)
- ULTT ( Upper limb tension test)
- NDI ( Neck Disability Index)

### MATERIALS USED IN THE STUDY

- Pen
- Goniometer
- Towel
- Couch
- Pillow
- Ultrasound therapy unit
- TENS

### PROCEDURE

After obtaining consent, 40 patients with cervical radiculopathy were assessed using the ULTT, NDI, NPRS, and Goniometer to determine the affected nerve, pain, and cervical and shoulder ROM. The patients were randomly assigned into two groups: Group A and Group B each consisting of 20 patients. The patients in Group A, known as the Control Group, received treatment using the Nerve Flossing Technique, USD, TENS, and patient-specific exercises. The patients in Group B, known as the Conventional Group, received treatment using TENS, USD, and exercises tailored according to each individual patient.

- Before intervention, all required procedure was demonstrated and well explained to the subjects by the principal investigator and asked to stop if any discomfort developed.
- Flossing was started from the root along with the brachial plexus, individual nerve, depending upon the involved nerve.

**FOR MEDIAN NERVE FLOSSING:**

- Patient lying in supine position
- The therapist sits beside the affected side.
- Extend the patient's arm so that the elbow is in level with the ground.
- Shoulder should be at 90 degrees.
- Wrist to be turned outward so the palm is facing up toward the ceiling. While extending the patient's wrist and instruct the patient to bend their neck toward the affected arm and to feel the stretch.
- Hold the arm in this position for 10 seconds.
- Follow it up by bringing the hand back to the starting position while laterally bending the patient's neck away from the arm.
- This pattern of movement is to be repeated 10 times.

**FOR ULNAR NERVE FLOSSING:**

- Patient lying in supine position
- The therapist sits beside the affected side.
- The patient is instructed by the therapist to extend their wrist, extend their elbow, and abduct their shoulder to 90 degrees.
- The patient is then told to draw a circle with his or her thumb and pointer finger, while simultaneously pronating and flexing their elbows and attempting to place the circle above their eye. At the same time bend the neck towards the affected side.
- Hold the arm in this position for 10 seconds.
- While returning to the starting position the patient is instructed to laterally flex the neck towards the unaffected side.
- This pattern of movement is to be repeated for 10 times.

**FOR RADIAL NERVE FLOSSING:**

- Patient in Standing position.
- The therapist passively extends the hand to 20 degrees with wrist and elbow in extension followed by internal rotation of shoulder joint.
- After that, the patient's wrist is stretched, and the affected side of their neck is bent to provide the desired stretch.
- This position is to be held for 10 sec and to be repeated .
- This can later on be progressed accordingly.
- Now while returning back to the starting position , bend the neck in the opposite direction.

**The patient should feel symptoms just slightly (pain, numbness, tingling). If the symptoms start to increase stop immediately.**

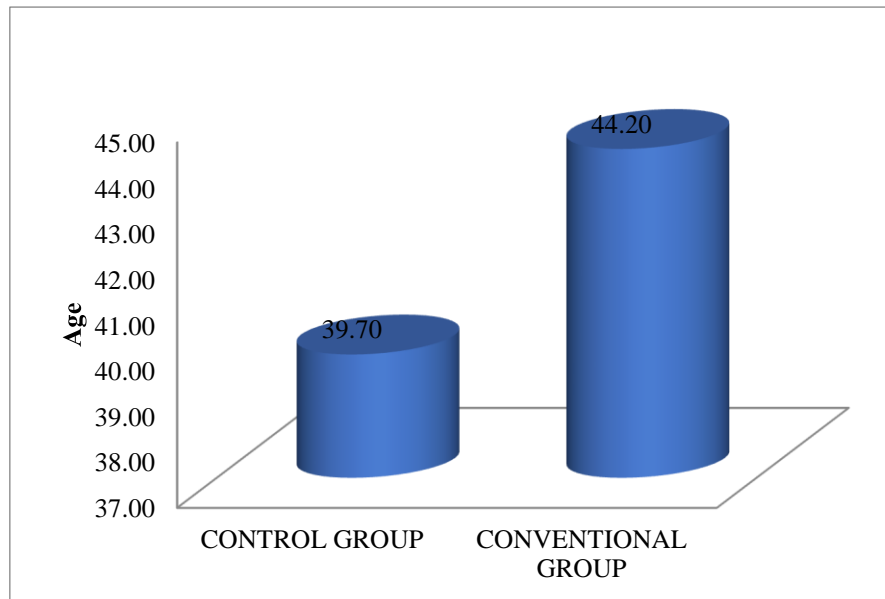
**IV. DATA ANALYSIS:****INTERPRETATION**

Statistical analysis of the data was done using SPSS 20.0. Categorical variables were presented using frequency and percentage. Descriptive statistics was expressed using mean, SD. Pre-post comparison was done by paired t-test and between-group comparison was done by unpaired t-tests. A p-value of <0.05 was considered statistically significant.

Table 1: Mean and SD of Age in Control and Conventional group

GROUP	N	Mean	Std. Deviation	t value	p value
CONTROL GROUP	20	39.70	11.82	1.273	.211
CONVENTIONAL GROUP	20	44.20	10.49		

In the Control group, the average age was  $39.7 \pm 11.82$  and in the Conventional group, the average age was  $44.2 \pm 10.49$ . The analysis shows that there is no significant difference in age between the groups with  $p > 0.05$ .

**Figure 1: Representation of Age****Table 2: Comparison of cervical ROM between the groups**

ROM		N	Mean	Std. Deviation	t value	p value
FLEXION	CONTROL GROUP	20	41.900	16.543	2.0710	.0440
	CONVENTIONAL GROUP	20	28.950	22.549		
EXTENTION	CONTROL GROUP	20	28.500	15.582	3.0090	.0050
	CONVENTIONAL GROUP	20	15.300	11.921		
LT ROTATION(right)	CONTROL GROUP	20	11.500	11.265	.5190	.6070
	CONVENTIONAL GROUP	20	13.450	12.467		
LT ROTATION(left)	CONTROL GROUP	20	14.750	14.621	.7460	.4610
	CONVENTIONAL GROUP	20	18.150	14.217		
SIDE FLEXION(right)	CONTROL GROUP	20	6.100	7.376	.4700	.6410
	CONVENTIONAL GROUP	20	7.250	8.091		
SIDE FLEXION(left)	CONTROL GROUP	20	10.050	8.101	.1530	.8790
	CONVENTIONAL GROUP	20	9.700	6.275		

The analysis shows significant differences between the groups in flexion and extension. Improvement is significantly more in the control group. Flexion in control:41.9 Vs conventional:28.9. Extension in control:28.5 Vs conventional:15.3.

Figure 2: Representation of Cervical ROM

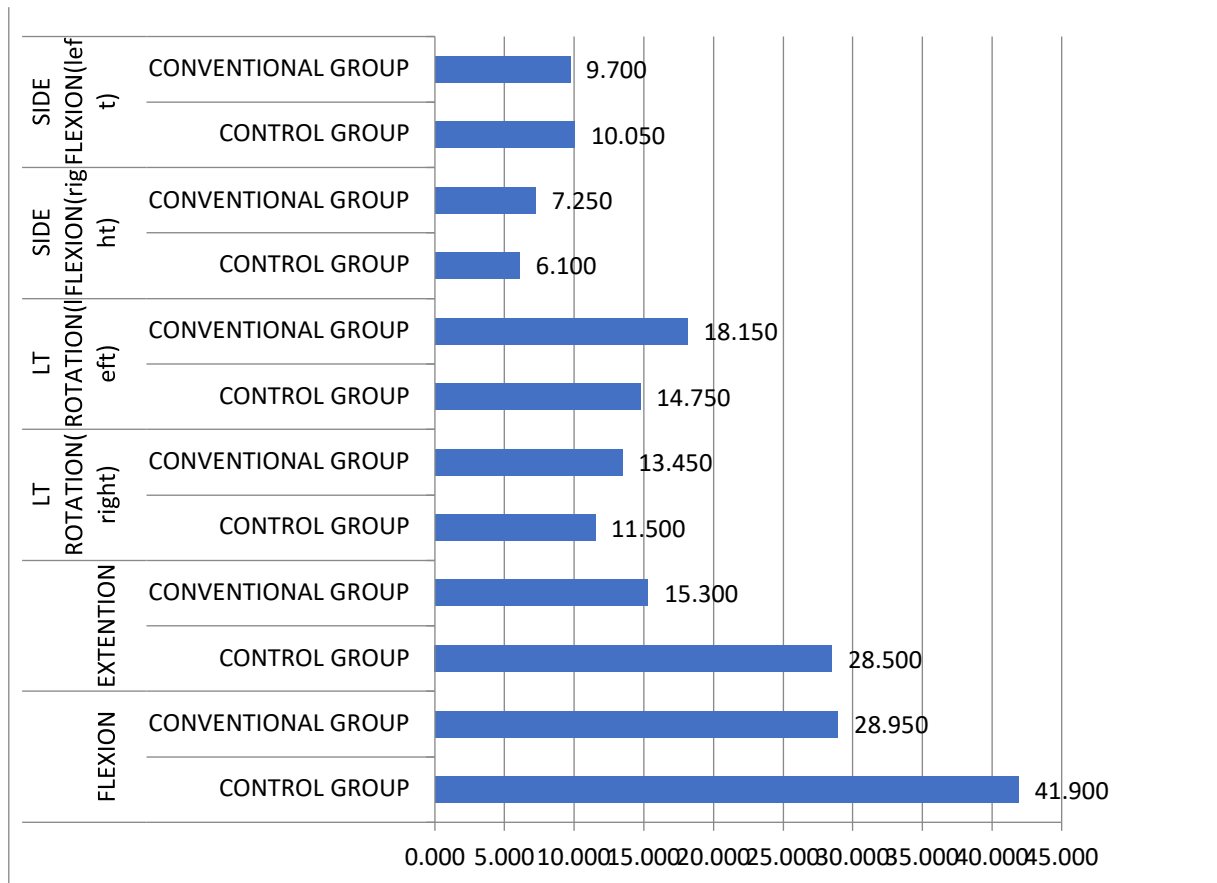
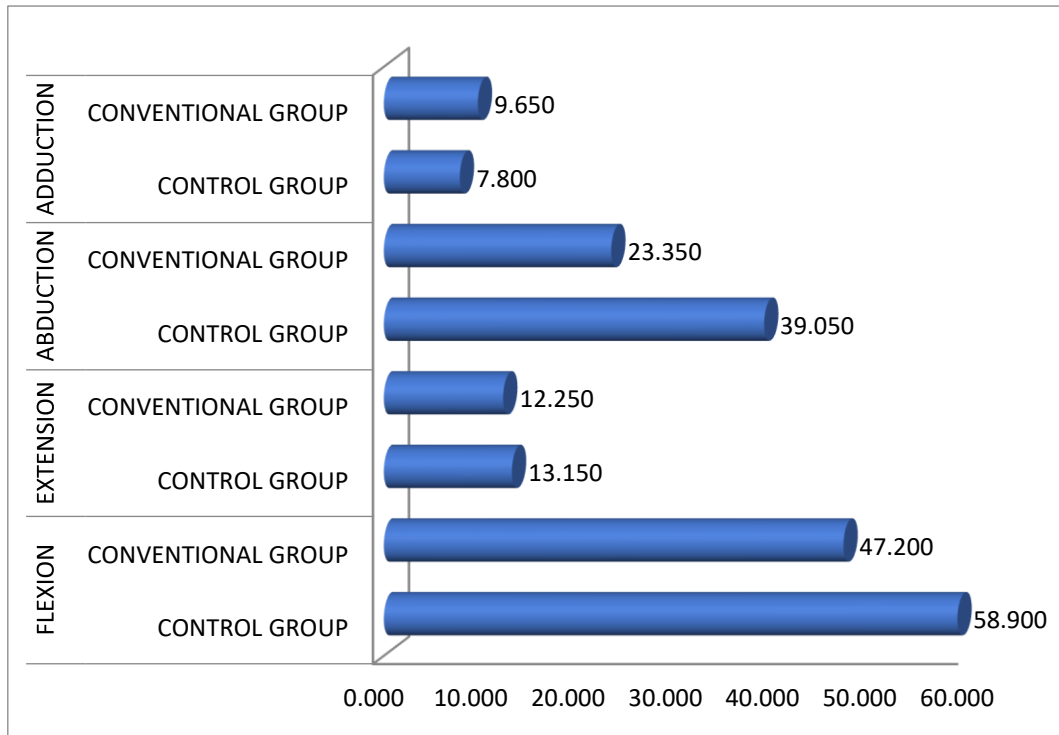


Table 3: Comparison of shoulder ROM between the groups

ROM	GROUP	Mean	Std. Deviation	t value	p value
FLEXION	CONTROL GROUP	58.900	46.13014	.791	.434
	CONVENTIONAL GROUP	47.200	47.42484		
EXTENSION	CONTROL GROUP	13.150	8.77361	.332	.742
	CONVENTIONAL GROUP	12.250	8.36581		
ABDUCTION	CONTROL GROUP	39.050	31.15745	1.424	.163
	CONVENTIONAL GROUP	23.350	38.22134		
ADDUCTION	CONTROL GROUP	7.800	8.31359	.605	.548
	CONVENTIONAL GROUP	9.650	10.84472		

Shoulder ROM improvement does not vary significantly between the control and conventional groups with  $p > 0.05$ .

Figure 3: Representation of Shoulder ROM



## V. DISCUSSION:

**On Comparing Group A and Group B**, the t value of NPRS was 1.782, the t value of NDI was 1.800, the t value of Cervical Flexion was 2.0710, the t value for Cervical Extension was 3.0090, the t value of Cervical lateral rotation (R) was 0.5190, the t value of Cervical lateral rotation (L) was 0.7460, the t value of Cervical side flexion (R) was 0.4700, the t value for Cervical side flexion (L) was 0.1530, the t value of Shoulder Flexion was 0.791, the t value for Shoulder Extension was 0.332, the t value for Shoulder Abduction was 1.424, the t value of Shoulder Adduction was 0.605.

The Analysis shows a slight improvement in NPRS, Cervical left-side flexion ROM, and Shoulder Extension ROM whereas the study showed that there was significantly more improvement in Cervical Flexion ROM, Cervical Extension ROM, Shoulder Flexion ROM and Shoulder Abduction in post-assessment.

Nerve flossing technique when performed dynamically, the pumping effect aids in venous return, edema dispersal and reduces the pressure inside the perineurium. By reducing sensitivity and restoring function, it lessens the hazard that an injury poses. This would minimize the potential for ion channel upgradation in the dorsal root ganglia and the central nervous system and limit the potential risk for dorsal root ganglia and brain alterations.<sup>4</sup>

## VI. CONCLUSION:

Based on the suggested mean values for the NPRS, NDI, Cervical ROM, and Shoulder ROM within and between Groups A and B, this study concludes that there has been a considerable improvement in both Groups. When comparing the two groups, Group A showed a substantial difference from Group B. The null hypothesis is rejected in light of the data analysis, interpretation, and clinical advancement, and the alternate hypothesis is accepted. Among the patients in Groups A and B, there was significant variance in terms of pain, cervical range of motion, and shoulder range of motion.

## LIMITATIONS AND RECOMMENDATIONS

Studies with a larger sample size can be undertaken in the future to achieve better results as this was conducted with a small sample size. This study demonstrated the treatment's immediate effectiveness; as a result, it is impossible to ascertain the treatment's long-term effects, which can only be determined by a longer-term study.

## VII. ACKNOWLEDGMENT:

I Thank Almighty god, sincere gratitude to my guide and all my friends. Last but not the least, I would like to thank all subjects of my study without whom this task would have been impossible. My sincere thanks to all the contributors whose name I have not mentioned but they all deserve my gratitude.

**REFERENCES:**

1. Dhuriya A, Katiyar N, Sethi AD. Effect of Combined Neural Mobilization and Intermittent Traction in Patients with Cervical Radiculopathy. *Journal of Physical Medicine Rehabilitation Studies & Reports*. SRC/JPMRS/137. DOI: doi.org/10.47363/JPMRS/2021 (3). 2021;129:2-4.
2. Rafiq S, Zafar H, Gillani SA, Waqas MS, Zia A, Liaqat S, Rafiq Y. Effectiveness of Neural Mobilization on Pain, Range of motion, and Disability in Cervical Radiculopathy: a Randomized Controlled Trial.
3. Iyer S, Kim HJ. Cervical radiculopathy. *Curr Rev Musculoskelet Med*. 2016 Sep;9(3):272-80. doi: 10.1007/s12178-016-9349-4. PMID: 27250042; PMCID: PMC4958381.
4. Vartak HS, Rajapurkar R, Palekar T, Saini S, Khisty A. A comparative study between neural mobilisation techniques versus nerve flossing technique in patients with acute sciatica. *International Journal of Basic and Applied Research*. 2019;9(3):909-22.
5. Mosby. *Rehabilitation of the Hand and Upper Extremity*. Inc., 2011:697.
6. Bhatia SS, Bid DD, Thangamani Ramalingam A. Effectiveness of nerve flossing technique in chronic lumbar radiculopathy. *Indian J Physiother Occup Ther*. 2017;11:44-9.
7. Srinivasulu M, Chunduri D. Comparing Mulligan Mobilization and Neural Mobilization Effects in Patients with Cervical Radiculopathy. *RGUHS Journal of Physiotherapy*. 2021;1(2).
8. Darshana D. Chaudhary, Neha Ingale, Kalyani Nagulkar et al. Comparison of nerve flossing and conventional therapy with only conventional therapy for sciatica. *Int. J. of Allied Med. Sci. and Clin. Research*. 2018: Vol-6(2); [269-276]
9. Ojoawo A, Nihinlola B. Effects of sustained natural apophyseal glides in the management of cervical radiculopathy. *International Journal of Medical Reviews and Case Reports*. 2019;(0):1.
10. Mallard F, LEMEUNIER N, Pierre CÔ. Effectiveness of Multimodal Rehabilitation Interventions for Management of Cervical Radiculopathy in Adults: An Updated Systematic Review from the Ontario Protocol for Traffic Injury Management (Optima) Collaboration. *Journal of rehabilitation medicine*. 2022;54.
11. [https://www.bobandbrad.com/\\_files/ugd/9a674f\\_9c4defd48a8b4eab96e7bcf6c644\\_11ad.pdf](https://www.bobandbrad.com/_files/ugd/9a674f_9c4defd48a8b4eab96e7bcf6c644_11ad.pdf)

**LIST OF ABBREVIATIONS :**

- **NPRS:** Numeric Pain Rating Scale
- **NDI:** Neck Disability Index
- **NFT:** Nerve Flossing Technique
- **CR:** Cervical Radiculopathy
- **ROM:** Range of Motion
- **L:** Left
- **R:** Right
- **USD:** Ultrasound
- **TENS:** Transcutaneous Electrical Nerve Stimulation
- **LT:** Lateral